



# Chapter 11

## Retina

### 11.1 Posterior Vitreous Detachment

#### Symptoms

Floater, blurred vision, and/or flashes of light which are more common in dim illumination or with eye movement. Symptoms usually present acutely and progress over hours to days.

#### Signs

**Critical.** One or more discrete near-translucent or light gray vitreous opacities, one often in the shape of a ring (“Weiss ring”) or broken ring, suspended over the optic disc (see Figure 11.1.1).

**Other.** Retinal break/tear (RT), retinal detachment (RD), or vitreous hemorrhage (VH) may occur with or without a posterior vitreous detachment (PVD), with similar symptoms. Peripheral retinal and disc margin hemorrhages, released retinal pigment epithelial cells in the anterior vitreous (“tobacco dust” or Shafer sign).

**NOTE:** Approximately 8% to 26% of all patients with acute symptomatic PVD have a retinal break. The presence of pigmented cells in the anterior vitreous or VH in association with an acute PVD indicates a high probability (>70%) of a coexisting retinal break. See 11.2, RETINAL BREAK.

#### Differential Diagnosis

- Uveitis: In vitritis, vitreous cells may be found in both the posterior and anterior vitreous, the condition may be bilateral, and the cells are not typically pigmented. Many uveitides, particularly white dot syndromes, will also present with floaters and photopsias. See 12.3, POSTERIOR UVEITIS.
- Migraine: Multicolored photopsias in a zig-zag pattern that obstructs vision lasts approximately 20 minutes. A headache may or may

not follow, and symptoms may be bilateral. Normal fundus examination. See 10.27, MIGRAINE.

#### Workup

1. History: Duration of symptoms? Distinguish retinal photopsias from the visual distortion of migraine, which may be accompanied by new floaters. Location of photopsias does not correlate with location of retinal break(s), if present. Risk factors for retinal break (trauma, previous intraocular surgery, yttrium aluminum garnet [YAG] laser capsulotomy, high myopia, personal or family history of RT/RD)?
2. Complete ocular examination, including evaluation of the anterior vitreous for pigmented cells and a dilated fundus examination with indirect ophthalmoscopy and scleral depression to rule out a retinal break and detachment. Optical coherence tomography (OCT) can be helpful in confirming the presence or absence of a PVD. Hyperreflective dots in the vitreous (“falling ash sign”), when present,

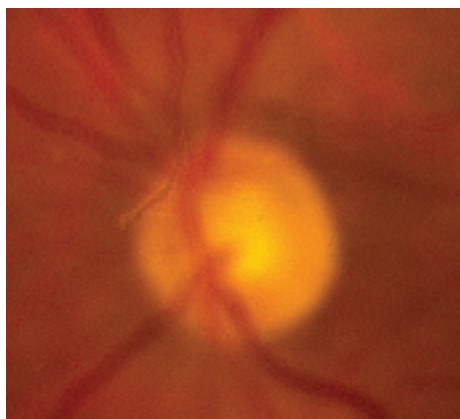



Figure 11.1.1 Posterior vitreous detachment.

have a high correlation with peripheral retinal breaks. Pseudophakic patients may have smaller anterior breaks compared to phakic patients. Examine the fellow eye to assess for presence of PVD and peripheral retinal pathology.

3. Visualize the PVD at the slit lamp with a 60- or 90-diopter lens by identifying a gray-to-black strand suspended in the vitreous. If not visible, have the patient make rapid saccades and then look straight to float the PVD into view.
4. If VH obscures visualization of the retina, ultrasonography (US) is indicated to identify the PVD and rule out a retinal break, RD, or other causes of vitreous hemorrhage. Inferior layering vitreous hemorrhage may mimic a retinal break on US. See 11.13, VITREOUS HEMORRHAGE.

### Treatment

No treatment is indicated for PVD unless an acute retinal break or dense vitreous hemorrhage is found; see 11.2, RETINAL BREAK.

 **NOTE:** In the setting of acute PVD symptoms, chronic retinal breaks (pigmented) or lattice degeneration usually warrant treatment.

### Follow Up

- The patient should be given a list of RD symptoms (a significant increase in floaters or flashing lights, worsening vision, or the appearance of a persistent curtain or shadow anywhere in the field of vision) and told to return immediately if these symptoms develop. The timing of symptoms could be anywhere from days to years later.
- Patients should be informed that they will also likely develop a PVD in their fellow eye, if not already present.
- If no retinal break or hemorrhage is found, the patient should be scheduled for repeat examination with scleral depression in 4 to 6 weeks. There is a 2% to 5% risk of developing new retinal breaks in patients with PVD and no retinal break at presentation.
- If no retinal break is found, but mild VH or peripheral punctate retinal hemorrhages are present (indicating increased vitreous traction), repeat examinations are performed in 2 weeks.
- If no retinal break is found but significant VH or anterior pigmented vitreous cells are present, repeat examination should be performed within 24 hours by a retina specialist because of the high likelihood of a retinal break.

## 11.2 Retinal Break (Tear)

### Symptoms

Acute retinal break: Flashes of light, floaters (“cobwebs,” “hair,” or “film” that changes position with eye movement) with or without visual acuity changes. Can be identical to PVD symptoms, though may be more profound.

Chronic retinal breaks or atrophic retinal holes: Usually asymptomatic.

### Signs

(See Figure 11.2.1.)

**Critical.** A full-thickness retinal defect, usually seen in the periphery.

**Other.** Acute retinal break: Pigmented cells in the anterior vitreous, VH, PVD, retinal flap, subretinal fluid (SRF), or an operculum (a free-floating piece of retina suspended above a RT).

Chronic retinal break: Surrounding pigmentation ring or demarcation line between attached and detached retina and signs (but not necessarily symptoms) of an acute retinal break.

### Predisposing Conditions

Lattice degeneration, high myopia, aphakia, pseudophakia, age-related retinoschisis, vitreoretinal tufts, meridional folds, history of previous retinal break or detachment in the fellow eye, family history of retinal break or detachment, collagen vascular disorders, and trauma.

### Differential Diagnosis

- Lattice degeneration.
- White without pressure: Abrupt changes in retinal pigmentation that may mimic a break or subretinal fluid. Benign findings, etiology unclear.

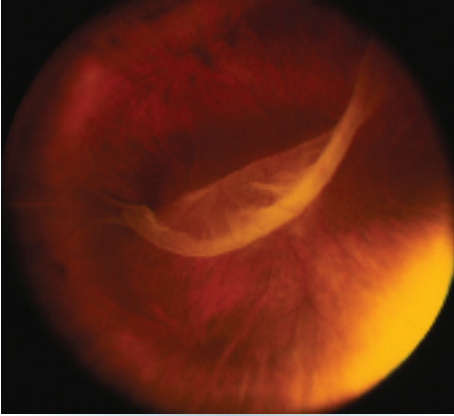


Figure 11.2.1 Giant retinal tear.

- Choroidal rupture or retinal hemorrhage (all layers): May occur without retinal break or obscure retinal break.
- Meridional fold: Small radial fold of retina perpendicular to the ora serrata and overlying an oral tooth; may have small retinal hole at the base.
- Vitreoretinal tuft: Focal area of vitreous traction causing elevation of the retina.

### Workup

Complete ocular examination with a slit lamp and indirect ophthalmoscopy of both eyes with scleral depression. After trauma, scleral depression may be gently performed once open globe injury has been ruled out. B-scan US may be helpful when the retina is not visible (e.g., vitreous hemorrhage, dense cataract, etc.)

## 11.3 Retinal Detachment

There are three distinct types of RD.

### RHEGMATOGENOUS RETINAL DETACHMENT

#### Symptoms

Flashes of light, floaters, a curtain or shadow moving over the field of vision, peripheral or central visual loss, or both.

#### Treatment

In general, laser therapy or cryotherapy is required within 24 hours for acute retinal breaks. Treatment may be less urgent for chronic breaks. However, each case must be individualized based on patient risk factors. We follow these general guidelines:

1. Treatment recommended:
  - Acute symptomatic break (e.g., a horseshoe or operculated tear).
  - Acute traumatic break (including a dialysis).
  - Acute symptoms and presence of lattice degeneration.
2. Treatment to be considered:
  - Asymptomatic retinal break that is large (e.g.,  $\geq 1.5$  mm), above the horizontal meridian, or both, particularly in the absence of PVD.
  - Asymptomatic retinal break in an aphakic or pseudophakic eye, a highly myopic eye, or an eye in which the involved or contralateral eye has had an RD.

#### Follow Up

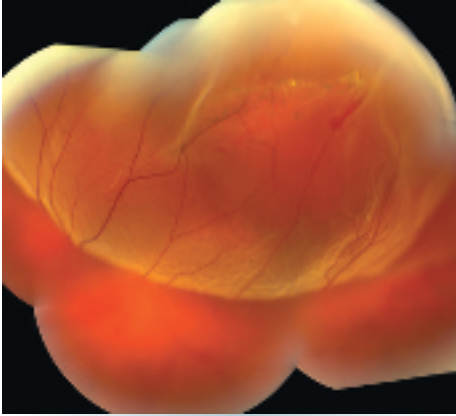
1. Patients with predisposing conditions or retinal breaks that do not require treatment are followed at 3 months and then every 6 to 12 months if stable.
2. Patients treated for a retinal break are reexamined in 2 weeks, 6 weeks, 3 months, and then every 6 to 12 months.
3. RD symptoms (a dramatic increase in floaters or flashing lights, worsening visual acuity, or the appearance of a curtain, shadow, or bubble anywhere in the field of vision) are explained and patients are told to return immediately if these symptoms develop.

#### Signs

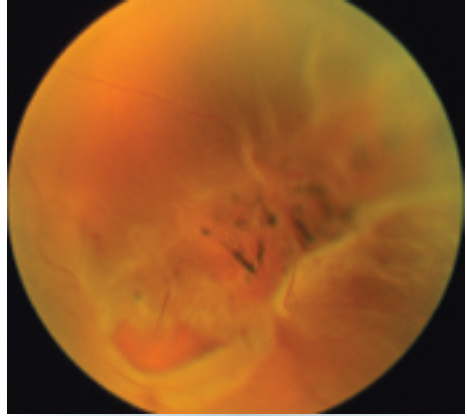
(See Figures 11.3.1 to 11.3.3.)

**Critical.** Elevation of the retina from the retinal pigment epithelium (RPE) by fluid in the subretinal space due to an accompanying full-thickness retinal break or breaks. See 11.2, RETINAL BREAK.

**Other.** Anterior vitreous pigmented cells; VH; PVD; may have low (due to increased fluid



**Figure 11.3.1** Rhegmatogenous retinal detachment.



**Figure 11.3.2** Retinal detachment with retinal break in lattice degeneration.

pumping through the RPE), high (Schwartz–Matsuo syndrome, released photoreceptors clogging trabecular meshwork), or normal intraocular pressure (IOP) in the affected eye. SRF is clear and does not shift with gravity. The detached retina is often corrugated and partially opaque in appearance. A mild relative afferent pupillary defect (RAPD) may be present in large RDs.

**NOTE:** A chronic rhegmatogenous retinal detachment (RRD) often shows a pigmented demarcation line at the posterior extent of the RD, intraretinal cysts, fixed folds, and/or subretinal precipitates or a combination of these with a relative visual field defect. It should be differentiated from retinoschisis, which is typically smooth and dome-shaped, translucent, and produces an absolute visual field defect. Underlying choroidal vasculature appears normal (unlike RRD, where it is obscured).

### Etiology

A retinal break allows fluid to move through the hole and separate the overlying retina from the RPE.

### Workup

1. Slit lamp examination to assess for signs of uveitis, lens status, presence of vitreous pigment/hemorrhage, and PVD.
2. Indirect ophthalmoscopy with scleral depression of both eyes. Slit lamp examination of the

periphery with a 90-diopter or widefield lens may help in finding small breaks.

3. B-scan US may be helpful if media opacities are present.

## EXUDATIVE/SEROUS RETINAL DETACHMENT

### Symptoms

Visual field defect with varying degrees of vision loss; visual changes may vary with changes in head position.

### Signs

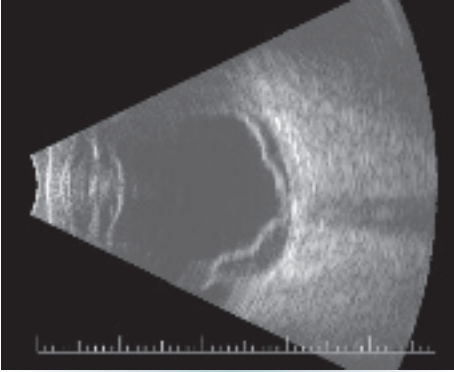
(See Figure 11.3.4.)

**Critical.** Serous elevation of the retina with shifting SRF with patient positioning. While sitting, the SRF accumulates inferiorly, detaching the inferior retina; while in the supine position, the fluid accumulates in the posterior pole, detaching the macula. There is no retinal break; fluid accumulation is due to breakdown of the normal blood–retinal barrier. The detachment typically does not extend to the ora serrata.

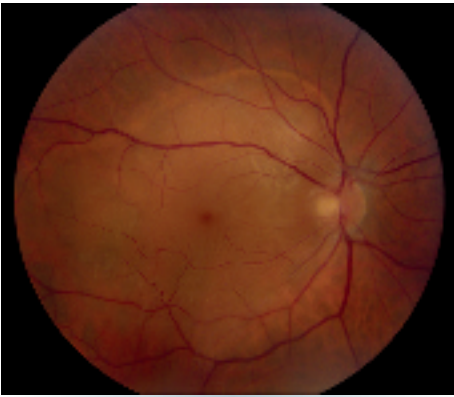**Other.** The detached retina is smooth and may become quite bullous. A mild RAPD may be present in large RDs.

### Etiology

- Neoplastic: Choroidal malignant melanoma, metastasis, choroidal hemangioma, multiple myeloma, retinal capillary hemangioblastoma, etc.

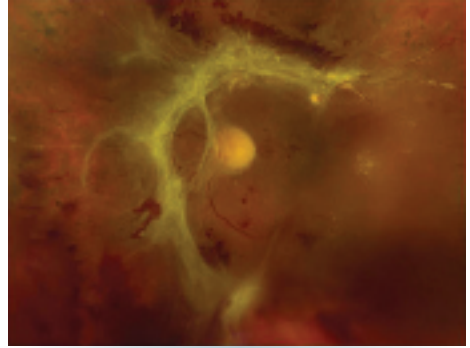


**Figure 11.3.3** B-scan ultrasonography of retinal detachment.



**Figure 11.3.4** Exudative retinal detachment.

- Inflammatory disease: Vogt–Koyanagi–Harada syndrome, posterior scleritis, sympathetic ophthalmia, other chronic inflammatory processes.
- Congenital abnormalities: Optic pit, morning glory syndrome, and choroidal coloboma (although these may have an associated retinal break).
- Vascular: Choroidal neovascularization (CNV), Coats disease, malignant hypertension (HTN), preeclampsia, and familial exudative vitreoretinopathy (FEVR). See specific sections.
- Idiopathic central serous chorioretinopathy (CSCR): May rarely present with bullous RD. See 11.15, CENTRAL SEROUS CHORIORETINOPATHY.
- Uveal effusion syndrome: Bilateral detachments of the peripheral choroid, ciliary body, and retina; leopard-spot RPE changes; vitreous cells; dilated episcleral vessels. More common



**Figure 11.3.5** Tractional retinal detachment.

in patients with high hyperopia, particularly nanophthalmic eyes.

### Workup

1. Intravenous fluorescein angiography (IVFA) may demonstrate leakage or pooling and identify the SRF source.
2. OCT may help identify the source of SRF (e.g., CNV).
3. B-scan US may help delineate the underlying cause.
4. Systemic workup to rule out the above causes.

## TRACTIONAL RETINAL DETACHMENT

### Symptoms

Visual loss or visual field defect; may be asymptomatic.

### Signs

(See Figure 11.3.5.)

**Critical.** A traction retinal detachment (TRD) appears concave with a smooth surface; cellular and vitreous membranes exerting traction on the retina are present; retinal striae extending from these areas may also be seen. Detachment may become a convex RRD if a tractional RT develops (combined RRD/TRD).

**Other.** The retina is immobile, and the detachment rarely extends to the ora serrata. A mild RAPD may be present in large RDs.

### Etiology

Fibrocellular bands in the vitreous (e.g., resulting from proliferative diabetic retinopathy [PDR],

sickle cell retinopathy, retinopathy of prematurity, FEVR, toxocariasis, trauma, proliferative vitreoretinopathy) contract and detach the retina.

### Workup

1. Slit lamp examination to assess lens status, sequelae of retinal vascular disease (e.g., neovascularization of the iris), and PVD.
2. Indirect ophthalmoscopy with scleral depression of both eyes. Slit lamp examination of the periphery with a 90-diopter or widefield lens may help in finding small breaks.
3. B-scan US may be helpful if media opacities are present.
4. OCT is useful in identifying tractional membranes and can be useful in differentiating tractional membranes from detached retina.

### Differential Diagnosis for All Three Types of Retinal Detachment

- Acquired/age-related degenerative retinoschisis: Commonly bilateral, smooth, bullous, usually inferotemporal. No pigmented cells or hemorrhage are present in the vitreous. Inner or outer retinal holes may be present. See 11.4, RETINOSCHISIS.
- X-linked retinoschisis: Petaloid foveal changes are present over 90% of the time. Dehiscence occurs in the nerve fiber layer (NFL) 50% of the time. See 11.4, RETINOSCHISIS.
- Choroidal detachment: Serous choroidal detachment: Orange-brown, more solid in appearance than an RD, often extends 360 degrees. Often secondary to hypotony

or inflammation. See 11.27, CHOROIDAL EFFUSION/DETACHMENT.

### Treatment

1. Patients with an acute RRD that threatens the macula should have surgical repair performed urgently. The visual prognosis is significantly worse in detachments that progress to involve the macula. Surgical options include laser photocoagulation, cryotherapy, pneumatic retinopexy, vitrectomy, and/or scleral buckle.
2. RRDs that are macula-off should be repaired, but are not necessarily urgent. Multiple studies suggest that visual outcomes for macula-off detachments do not change if surgery is performed within 7 to 10 days of the onset.
3. Chronic macula-off RDs are treated within 1 week if possible.
4. TRDs may or may not require intervention depending on etiology, status of the fellow eye, and the extent/location of retinal traction.
5. For exudative RDs, successful treatment of the underlying condition often leads to resolution of the detachment.

### Follow Up

All patients with RRD require urgent follow up with a retina specialist. After surgery, these patients are typically followed at 1 day, 1 week, 1 month, 2 to 3 months, and then every 6 to 12 months. Follow up for serous RD and TRD depends on underlying etiology and individual patient factors.

## 11.4 Retinoschisis

Retinoschisis, a splitting of the retina, occurs in X-linked (juvenile) and age-related (degenerative) forms.

### X-LINKED (JUVENILE) RETINOSCHISIS

#### Symptoms

Decreased vision due to macular involvement. Sometimes VH. Can be asymptomatic. The condition is congenital but may not be detected at birth if an examination is not performed. A family history may or may not be elicited (X-linked recessive).

#### Signs

**Critical.** Foveal schisis seen as stellate maculopathy: Cystoid foveal changes with retinal folds that radiate from the center of the fovea (petaloid pattern). Unlike the cysts of cystoid macular edema (CME), they do not stain or leak on IVFA, but can be seen with indocyanine green angiography (ICGA) and on OCT. The macular appearance changes in adulthood and the petaloid pattern may disappear.

**Other.** Classically taught as separation of the NFL from the outer retinal layers in the retinal periphery (bilaterally in the inferotemporal

quadrant, most commonly) with the development of NFL breaks; this peripheral retinoschisis occurs in 50% of patients. However, schisis may occur between any two retinal layers, and recent evidence suggests that the outer plexiform layer is frequently separated in X-linked forms. RD, VH, and pigmentary changes may also occur. Pigmented demarcation lines may be seen (indicating previous RD) even in the absence of active detachment, unlike acquired age-related degenerative retinoschisis.

### Differential Diagnosis

- Age-related (degenerative) retinoschisis. See Age-Related (Degenerative) Retinoschisis.
- RRD: Usually unilateral, acquired, and associated with a RT. Pigment in the anterior vitreous is seen. See 11.3, RETINAL DETACHMENT.

### Workup

1. Family history.
2. Dilated retinal examination with scleral depression to rule out retinal break or detachment.
3. OCT can help determine the layer of schisis and help to differentiate schisis from an RD.
4. IVFA will show no leakage.
5. Fundus autofluorescence (FAF) may help delineate areas of schisis.
6. Electroretinography (ERG) is not necessary for diagnosis but can show a reduced b-wave with a preserved a-wave.

### Treatment

1. No definitive treatment for stellate maculopathy. Topical carbonic anhydrase inhibitors have been shown to decrease foveal thickness and improve visual acuity in some patients.
2. For nonclearing VH, consider vitrectomy.
3. Surgical repair of an RD should be performed.
4. Superimposed amblyopia may be present in children younger than 11 years of age when one eye is more severely affected, and a trial of patching should be considered. See 8.7, AMBLYOPIA.

### Follow Up

Every 6 months; more frequently if treating amblyopia.

## AGE-RELATED (DEGENERATIVE) RETINOSCHISIS

### Symptoms

Usually asymptomatic; may have decreased vision.

### Signs

(See Figure 11.4.1.)

**Critical.** The schisis cavity is dome-shaped with a smooth surface and is usually located temporally, typically inferotemporally. The findings are usually bilateral and may show sheathing of retinal vessels and “snowflakes” or “frosting” (persistent Mueller fibers) on the elevated inner wall of the schisis cavity. Splitting usually occurs at the level of the outer plexiform layer. The area of schisis is not mobile and there is no associated RPE pigmentation in contrast to an RD, which may have corrugations and a pigmented demarcation line.

**Other.** Prominent cystoid degeneration near the ora serrata, an absolute scotoma corresponding to the area of schisis, hyperopia is common, no pigment cells or hemorrhage in the vitreous, and absence of a demarcation line. An RRD may occasionally develop.

### Differential Diagnosis

- RRD: Surface is corrugated in appearance and moves more with eye movements. A long-standing RD may resemble retinoschisis, but intraretinal cysts, demarcation lines between attached and detached retina, and

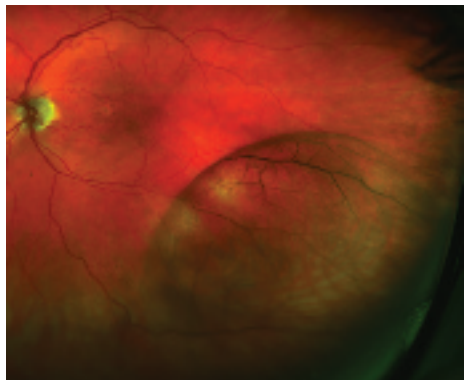


Figure 11.4.1 Retinoschisis.

white subretinal dots may be seen. Only a relative scotoma is present. See 11.3, RETINAL DETACHMENT.

- X-linked juvenile retinoschisis (see above).

### Workup

1. Slit lamp evaluation for anterior chamber inflammation and pigmented anterior vitreous cells; neither should be present in isolated retinoschisis.
2. Dilated retinal examination with scleral depression to rule out a concomitant RD or an outer layer retinal hole, which may lead to an RD.
3. A slit lamp examination using a 90-diopter lens or fundus contact lens as needed to aid in recognizing outer layer retinal breaks.
4. OCT can help determine which layer of the retina is split.

5. Visual field testing will reveal an absolute scotoma in the area of schisis.

### Treatment

1. Surgery is indicated when a clinically significant RD develops.
2. A small RD walled off by a demarcation line is usually not treated. This may take the form of pigmentation at the posterior border of outer layer breaks.

### Follow Up

Every 6 months. RD symptoms (an increase in floaters or flashing lights, blurry vision, or the appearance of a curtain or shadow anywhere in the field of vision) are explained to all patients, and patients are told to return immediately if these symptoms develop.

## 11.5 Cotton–Wool Spot

### Symptoms

Visual acuity usually normal. Often asymptomatic.

### Signs

(See Figure 11.5.1.)

**Critical.** Localized whitening in the superficial retinal NFL with fluffy appearance to margins

**NOTE:** The presence of even a single cotton-wool spot (CWS) is not normal. In a patient without diabetes mellitus, acute changes in blood pressure (most commonly hypertension), or a retinal vein occlusion, a workup for an underlying systemic condition should be performed.

### Differential Diagnosis

- Retinal whitening secondary to infectious retinitis, such as that seen in toxoplasmosis, herpes simplex virus, varicella zoster virus, and cytomegalovirus. These entities typically have vitritis and retinal hemorrhages associated with them. See 12.5, TOXOPLASMOSIS and 12.8, ACUTE RETINAL NECROSIS (ARN).
- Myelinated NFL: Develops postnatally. Usually peripapillary but may be in retinal areas remote from the disc (see Figure 11.5.2).

### Etiology

Thought to be an acute obstruction of a precapillary retinal arteriole causing blockage of axoplasmic flow and subsequent buildup of axoplasmic debris in the NFL.

- Diabetes mellitus: Most common cause. Often associated with microaneurysms, dot-blot hemorrhages, and hard exudates. See 11.12, DIABETIC RETINOPATHY.
- Chronic or acute HTN: May see retinal arteriolar narrowing and flame hemorrhages in

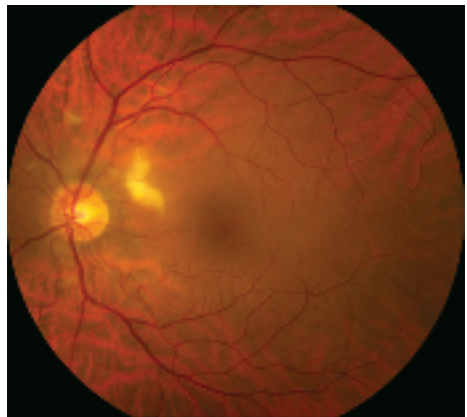


Figure 11.5.1 Cotton-wool spot.



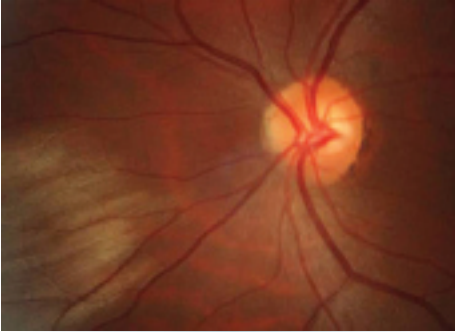


Figure 11.5.2 Myelinated nerve fiber layer.

chronic HTN. Acute HTN may have hard exudates, optic nerve swelling, exudative RD. See 11.10, HYPERTENSIVE RETINOPATHY.

- Retinal vein occlusion: Unilateral, multiple hemorrhages, venous dilation, and tortuosity. Multiple CWSs, usually  $\geq 6$ , seen in ischemic varieties. See 11.8, CENTRAL RETINAL VEIN OCCLUSION and 11.9, BRANCH RETINAL VEIN OCCLUSION.
- Retinal emboli: Often from carotid arteries or heart with resulting ischemia and subsequent CWS distal to arterial occlusion. Patients require carotid Doppler examination and echocardiography. See 10.22, TRANSIENT VISUAL LOSS/AMAUSIS FUGAX.
- Collagen vascular disease: Systemic lupus erythematosus (most common), granulomatosis with polyangiitis (formerly Wegener granulomatosis), polyarteritis nodosa, scleroderma, etc.
- Giant cell arteritis (GCA): Age  $\geq 55$  years. Symptoms include vision loss, scalp tenderness, jaw claudication, proximal muscle aches, etc. See 10.17, ARTERITIC ISCHEMIC OPTIC NEUROPATHY (GIANT CELL ARTERITIS).
- HIV retinopathy: Single or multiple CWSs in the posterior pole. See 12.10, NONINFECTIOUS RETINAL MICROVASCULOPATHY/HIV RETINOPATHY.
- Other infections: Toxoplasmosis, orbital zygomyces, Lyme disease, leptospirosis, Rocky Mountain spotted fever, onchocerciasis, subacute bacterial endocarditis, others.
- Hypercoagulable state: Polycythemia, multiple myeloma, cryoglobulinemia, Waldenström macroglobulinemia, antiphospholipid syndrome, factor V Leiden, activated protein C resistance, hyperhomocysteinemia, protein C

and S deficiency, antithrombin III mutation, prothrombin mutation, etc.

- Radiation retinopathy: Follows radiation therapy to the eye or periorcular structures when the eye is irradiated inadvertently. May occur any time after radiation, but occurs most commonly within a few years. Maintain a high suspicion even in patients in whom the eye was reportedly shielded. Usually, 3,000 cGy is necessary, but it has been noted to occur with 1,500 cGy. Resembles diabetic retinopathy.
- Interferon therapy.
- Purtscher and pseudo-Purtscher retinopathy: Multiple CWSs and/or superficial hemorrhages in a peripapillary configuration. Typically bilateral but can be unilateral and asymmetric. See 3.20, PURTSCHER RETINOPATHY.
- Cancer: Metastatic carcinoma, leukemia, lymphoma, others.
- Others: Migraine, hypotension, intravenous drug use, papilledema, papillitis, severe anemia, sickle cell, acute blood loss, etc.

## Workup

1. History: Diabetes or HTN? Prior ocular or periorcular radiation? GCA symptoms in appropriate age group? Symptoms of collagen vascular disease including joint pain, rashes, etc.? HIV risk factors? Hematologic abnormalities?
2. Complete ocular examination, including dilated retinal examination with a slit lamp and a 60- or 90-diopter lens and indirect ophthalmoscopy. Look for concurrent hemorrhages, vascular occlusion, vasculitis, hard exudates.
3. Check blood pressure.
4. Check fasting blood sugar and hemoglobin A1c.
5. Consider erythrocyte sedimentation rate (ESR), C-reactive protein (CRP), and platelets if GCA suspected.
6. Consider blood and urine cultures, chest x-ray, carotid and orbital Doppler examination, chest computed tomography (CT), and echocardiography if emboli are suspected.
7. Consider HIV testing.
8. Fluorescein angiography is generally not helpful for an isolated CWS without concomitant pathology. IVFA reveals areas of capillary nonperfusion adjacent to CWS location.

## Treatment

Identify and treat underlying etiology.

## Follow Up

Depends on underlying etiology. If concern for infectious process, serial dilated examinations

are recommended. CWSs typically fade in 5 to 7 weeks but can remain longer if associated with diabetic retinopathy.

# 11.6 Central Retinal Artery Occlusion

## Symptoms

Unilateral, painless, acute vision loss (counting fingers to light perception in 94% of eyes) occurring over seconds; may have a history of transient visual loss (amaurosis fugax).

## Signs

(See Figure 11.6.1.)

**Critical.** Superficial opacification or whitening of the retina in the posterior pole and a cherry-red spot in the center of the macula (may be subtle).

**Other.** Marked RAPD. Narrowed retinal arterioles; boxcarring or segmentation of the blood column in the arterioles. Occasionally, retinal arteriolar emboli or cilioretinal artery sparing of the foveola is evident. If visual acuity is light perception or worse, strongly suspect ophthalmic artery occlusion.

## Differential Diagnosis

- Acute ophthalmic artery occlusion: Usually no cherry-red spot; the entire retina appears whitened. Increased concern for GCA.

- Commotio retinae: Retinal whitening from intracellular edema and fragmentation of the photoreceptor outer segments and RPE. Follows blunt trauma, resolves spontaneously. May result in permanent retinal damage. May mimic a cherry-red spot when the posterior pole is involved (Berlin edema). See 3.17, COMMOTIO RETINAE.
- Other causes of a cherry-red spot: Tay-Sachs, Niemann-Pick disease type A, others. These conditions present early in life with other, often severe, systemic manifestations. Ophthalmic findings are usually bilateral.

## Etiology

- Embolus: Three main types include cholesterol, calcium, and platelet-fibrin emboli. All are seen within a vessel. Cholesterol emboli (Hollenhorst plaque) are typically refractile, yellow, and seen at retinal vessel bifurcations. They arise from ulcerated atheromas, usually from the carotid arteries. Calcium emboli are white and frequently cause distal retinal infarction. They typically arise from cardiac valves. Platelet-fibrin emboli are a dull white and typically arise from atheromas in the carotid arteries.
- Thrombosis.
- GCA: May produce central retinal artery occlusion (CRAO), branch retinal artery occlusion (BRAO), ophthalmic artery occlusion, or an ischemic optic neuropathy. See 10.17, ARTERITIC ISCHEMIC OPTIC NEUROPATHY (GIANT CELL ARTERITIS).
- Other collagen vascular disease: Systemic lupus erythematosus, polyarteritis nodosa, others.
- Hypercoagulable state: Polycythemia, multiple myeloma, cryoglobulinemia, Waldenström macroglobulinemia, antiphospholipid syndrome, factor V Leiden, activated protein C resistance, hyperhomocysteinemia, protein C

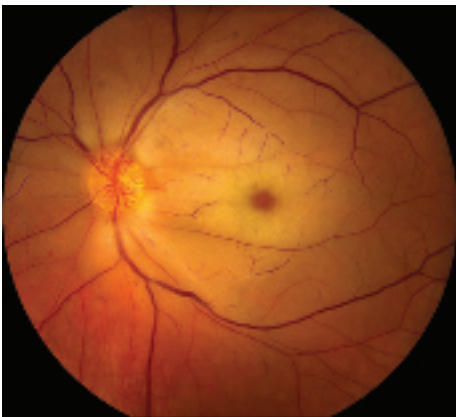

Figure 11.6.1 Central retinal artery occlusion.

and S deficiency, antithrombin III mutation, prothrombin mutation, etc.

- Rare causes: Migraine, Behçet disease, syphilis, sickle cell disease.
- Trauma.

### Workup

1. Should be treated as an acute stroke. The American Academy of Ophthalmology (AAO) 2018 guidelines suggest that all these patients should be sent immediately to an emergency department, preferably affiliated with a stroke center, for evaluation and workup.
2. Immediate ESR, CRP, and platelets to rule out GCA if the patient is 55 years of age or older and no embolus seen on examination. Query GCA review of systems. If the patient's history, laboratories, or both are consistent with GCA, start high-dose systemic steroids. See 10.17, ARTERITIC ISCHEMIC OPTIC NEUROPATHY (GIANT CELL ARTERITIS).
3. Check the blood pressure.
4. Other blood tests: Fasting blood sugar and hemoglobin A1c, complete blood count (CBC) with differential, prothrombin time/activated partial thromboplastin time (PT/PTT). In patients younger than 50 years or with appropriate risk factors or positive review of systems, consider lipid profile, antinuclear antibody (ANA), rheumatoid factor, syphilis testing (RPR or VDRL and FTA-ABS or treponemal-specific assay), serum protein electrophoresis, hemoglobin electrophoresis, and further evaluation for hypercoagulable state (see above).
5. Carotid artery evaluation by duplex Doppler US.
6. Cardiac evaluation with electrocardiography (ECG), echocardiography, and possibly Holter monitoring or bubble study.

7. OCT can be very helpful in making the diagnosis. Can also consider IVFA. Less commonly ERG is used.

### Treatment

CRAO is treated as an acute stroke and immediate referral to an emergency department with an affiliated stroke center is warranted. If GCA suspected, see 10.17, ARTERITIC ISCHEMIC OPTIC NEUROPATHY (GIANT CELL ARTERITIS) for treatment recommendations.

For specific management of ocular signs and symptoms, there are anecdotal reports of improvement after the following treatments, if instituted within 90 to 120 minutes of the occlusive event. None of these treatments have been proven effective in randomized, controlled clinical trials and should not be considered standard of care.

1. Immediate ocular massage with fundus contact lens or digital massage.
2. Anterior chamber paracentesis: See Appendix 13, ANTERIOR CHAMBER PARACENTESIS.
3. IOP reduction with acetazolamide, 500 mg i.v. or two 250-mg tablets p.o. or a topical beta-blocker (e.g., timolol or levobunolol, 0.5% daily or b.i.d.).

### Follow Up

1. Follow as directed by managing internist and/or neurologist.
2. Repeat eye examination in 1 to 4 weeks, checking for neovascularization of the iris/disc/angle/retina (NVI/NVD/NVA/NVE), which develops in up to 20% of patients at a mean of 4 weeks after onset. If neovascularization develops, perform panretinal photocoagulation (PRP) and/or administer an anti-vascular endothelial growth factor (anti-VEGF) agent.

## 11.7 Branch Retinal Artery Occlusion

### Symptoms

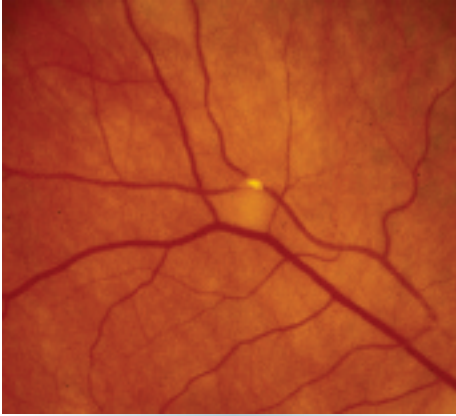
Unilateral, painless, abrupt change in vision, usually partial visual field loss; may have a history of transient visual loss (amaurosis fugax).

### Signs

(See Figure 11.7.1.)

**Critical.** Superficial opacification or whitening along the distribution of a branch retinal artery. The affected retina becomes edematous.

**Other.** Narrowed branch retinal artery; boxcarring, segmentation of the blood column, or emboli are sometimes seen in the affected branch retinal artery. Cholesterol emboli appear as bright,



**Figure 11.7.1** Branch retinal artery occlusion with Hollenhorst plaque.

reflective crystals, usually at a vessel bifurcation. CWSs may appear in the involved area.

### Etiology

See 11.6, CENTRAL RETINAL ARTERY OCCLUSION.

### Workup

See 11.6, CENTRAL RETINAL ARTERY OCCLUSION. Unlike in CRAO, an ERG is not helpful.



**NOTE:** When a BRAO is accompanied by optic nerve edema or retinitis, obtain appropriate serologic testing to rule out cat-scratch disease (*Bartonella [Rochalimaea] henselae*), syphilis, Lyme disease, and toxoplasmosis.

### Treatment

1. The AAO 2018 guidelines suggest that all these patients should be sent immediately to an emergency department, preferably affiliated with a stroke center, for evaluation and workup. See treatment in 11.6, CENTRAL RETINAL ARTERY OCCLUSION.
2. No ocular therapy of proven value is available.
3. Treat any underlying medical problem.

### Follow Up

1. Patients need immediate evaluation to treat any underlying disorders (especially GCA).
2. Reevaluate every 3 to 6 months initially to monitor progression. Ocular neovascularization after BRAO is rare.

## 11.8 Central Retinal Vein Occlusion

### Symptoms

Painless loss of vision, usually unilateral.

### Signs

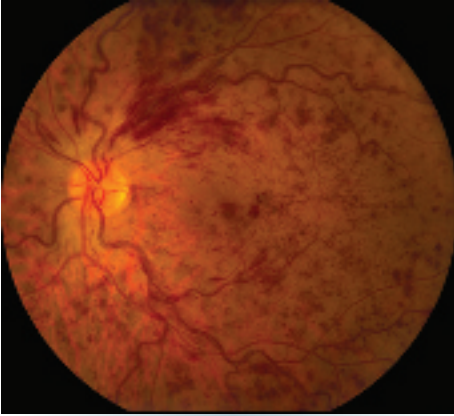
(See Figure 11.8.1.)

**Critical.** Diffuse retinal hemorrhages in all four quadrants of the retina; dilated, tortuous retinal veins.

**Other.** CWSs; disc edema and hemorrhages; macular edema (ME); optociliary collateral vessels on the disc (later finding); NVD, NVI, NVA, and NVE.

### Differential Diagnosis

- Ocular ischemic syndrome (OIS) or carotid occlusive disease: Dilated and irregular veins without tortuosity. Midperipheral retinal hemorrhages are typically present, but disc edema and disc hemorrhages are not characteristic. NVD is present in one-third of cases. Patients may have a history of transient visual loss (amaurosis fugax), transient ischemic attacks, or orbital pain. IOP may be decreased. May have pain or intraocular inflammation. Can have abnormal ophthalmodynamometry. See 11.11, OCULAR ISCHEMIC SYNDROME/CAROTID OCCLUSIVE DISEASE.
- Diabetic retinopathy: Hemorrhages and microaneurysms concentrated in the posterior pole. Typically bilateral. IVFA differentiates this condition from central retinal vein occlusion (CRVO). See 11.12, DIABETIC RETINOPATHY.
- Papilledema: Bilateral disc swelling with flame-shaped hemorrhages surrounding the disc. Would not expect as extensive and diffuse



**Figure 11.8.1** Central retinal vein occlusion with dilated, tortuous vasculature, diffuse retinal hemorrhages in all four quadrants, and macular edema.

retinal hemorrhage and vascular tortuosity. See 10.15, PAPILLEDEMA.

- Radiation retinopathy: History of irradiation. Disc swelling with radiation papillopathy and retinal neovascularization may be present. Generally, CWSs are a more prominent feature than hemorrhages.

### Etiology

- Atherosclerosis of the adjacent central retinal artery: The artery compresses the central retinal vein in the region of the lamina cribrosa, secondarily inducing thrombosis in the vein lumen.
- HTN: Most common systemic disease associated with CRVO.
- Optic disc edema.
- Glaucoma: Most common ocular disease associated with CRVO.
- Optic disc drusen.
- Hypercoagulable state: Polycythemia, multiple myeloma, cryoglobulinemia, Waldenström macroglobulinemia, antiphospholipid syndrome, factor V Leiden, activated protein C resistance, hyperhomocysteinemia, protein C and S deficiency, antithrombin III mutation, prothrombin mutation, and others.
- Vasculitis: Sarcoidosis, syphilis, systemic lupus erythematosus, and others.
- Drugs: Oral contraceptives, diuretics, and others.

- Abnormal platelet function.
- Orbital disease: Thyroid eye disease, orbital tumors, arteriovenous fistula, and others.
- Migraine: Rare.

### Types

- Ischemic CRVO: Vision typically worse (<20/200) with RAPD and visual field defects. Extensive retinal hemorrhage, CWSs, venous tortuosity, and widespread capillary nonperfusion on IVFA (often >10 disc diameters). ERG shows decreased b-wave amplitude. Higher risk of neovascularization.
- Nonischemic CRVO: Vision often better than 20/200, mild or no RAPD, mild fundus changes. Lower risk of neovascularization.

### Workup

#### Ocular

1. Complete ocular examination, including IOP measurement, careful slit lamp examination and gonioscopy to rule out NVI and NVA (both of which are best observed before dilation), and dilated fundus examination.
2. IVFA: Risk of neovascularization proportional to degree of capillary nonperfusion.
3. OCT: Used to help detect presence and extent of ME as well as to monitor response to therapy.
4. If the diagnosis is uncertain, oculopneumoplethysmography or ophthalmodynamometry may help to distinguish CRVO from carotid disease (but are infrequently performed). Ophthalmic artery pressure is low in carotid disease but is normal to increased in CRVO.

#### Systemic

1. History: Medical problems, medications (especially antihypertensive medications, oral contraceptives, diuretics), eye diseases?
2. Check blood pressure.
3. Blood tests: Fasting blood sugar and hemoglobin A1c, CBC with differential, platelets, PT/PTT, lipid profile.
4. If clinically indicated, particularly in younger patients, consider hemoglobin electrophoresis, RPR or VDRL, FTA-ABS or treponemal-specific assay, ANA, cryoglobulins, antiphospholipid antibodies, factor V Leiden mutation, protein C and S levels, antithrombin III

mutation, prothrombin mutation, homocysteine levels, serum protein electrophoresis, and chest radiograph.

5. Complete medical evaluation, with careful attention to cardiovascular disease or hypercoagulability.

## Treatment

1. Discontinue oral contraceptives; change diuretics to other antihypertensive medications if possible.
2. Reduce IOP if increased in either eye. See 9.1, PRIMARY OPEN-ANGLE GLAUCOMA.
3. Treat underlying medical disorders.
4. If NVI or NVA is present, perform PRP promptly. Consider PRP if NVD or retinal neovascularization is present. Prophylactic PRP for nonperfusion is usually not recommended unless follow up is in doubt. Intravitreal VEGF inhibitors are very effective in temporarily halting or reversing anterior and posterior segment neovascularization. They may be a useful adjunct to PRP, particularly when rapid reversal of neovascularization is needed.
5. Aspirin 81 to 325 mg p.o. daily is often recommended, but no clinical trials have demonstrated efficacy to date, and it may increase the risk of hemorrhage.

## CRVO-Related Macular Edema

1. Intravitreal ranibizumab 0.5 mg and aflibercept 2 mg are US Food and Drug Administration (FDA)-approved for treating RVO-related ME. Intravitreal bevacizumab has been used off-label in a similar fashion. Risks of intravitreal injections are low but include VH and endophthalmitis, among others.
2. Dexamethasone intravitreal implant, a biodegradable 0.7 mg implant, is FDA-approved for the treatment of ME associated with retinal vein occlusion. Off-label intravitreal steroid (e.g., triamcinolone 40 mg/mL, injecting 1 to 4 mg) can also be considered and has been effective in both improving vision and reducing vision loss in patients with ME secondary to CRVO. Complications include cataract formation and elevated IOP.



**NOTE:** In a large, prospective, randomized trial (SCORE-CRVO), a 1 mg dose of intravitreal triamcinolone was found to be equally as effective as a 4 mg dose, but with fewer side effects (elevated IOP and cataract formation).

## Follow Up

1. Every month initially, with gradual interval taper based on vision, presence of ME, and response to treatment.
2. At each follow-up visit, evaluate anterior segment for NVI and assess presence/absence of NVA with undilated gonioscopy, followed by careful dilated fundus examination looking for NVD or other retinal neovascularization. Evidence of early NVI or NVA should prompt immediate PRP and/or anti-VEGF therapy and monthly follow up until stabilized or regressed.
3. Patients should be informed that there is an 8% to 10% risk for the development of a branch retinal vein occlusion (BRVO) or CRVO in the fellow eye.

## REFERENCES

- Brown DM, Campochiaro PA, Singh RP, et al. Ranibizumab for macular edema following central retinal vein occlusion: six-month primary end point results of a phase III study. *Ophthalmology*. 2010;117(6):1124-1133.
- Haller JA, Bandello F, Belfort R Jr, et al. Randomized sham-controlled trial of dexamethasone intravitreal implant in patients with macular edema due to retinal vein occlusion. *Ophthalmology*. 2010;117(6):1134-1146.
- Ip MS, Scott IU, VanVeldhuisen PC, et al. A randomized trial comparing the efficacy and safety of intravitreal triamcinolone with observation to treat vision loss associated with macular edema secondary to central retinal vein occlusion: the Standard Care vs Corticosteroid for Retinal Vein Occlusion (SCORE) study report 5. *Arch Ophthalmol*. 2009;127(9):1101-1114.
- Boyer D, Heier J, Brown DM, et al. Vascular endothelial growth factor Trap-Eye for macular edema secondary to central retinal vein occlusion: six-month results of the Phase III COPERNICUS Study. *Ophthalmology*. 2012;119:1024-1032.

## 11.9 Branch Retinal Vein Occlusion

### Symptoms

Blind spot in the visual field or loss of vision, usually unilateral.

### Signs

(See Figure 11.9.1.)

**Critical.** Superficial hemorrhages in a sector of the retina along a retinal vein. The hemorrhages usually do not cross the horizontal raphe (midline).

**Other.** CWSs, retinal edema, a dilated and tortuous retinal vein, narrowing and sheathing of the adjacent artery, retinal neovascularization, VH.

### Differential Diagnosis

- Diabetic retinopathy: Dot-blot hemorrhages and microaneurysms extend across the horizontal raphe. Nearly always bilateral. See 11.12, DIABETIC RETINOPATHY.
- Hypertensive retinopathy: Narrowed retinal arterioles. Hemorrhages are not confined to a sector of the retina and usually cross the horizontal raphe. Bilateral in most. See 11.10, HYPERTENSIVE RETINOPATHY.

### Etiology

Disease of the adjacent arterial wall (usually secondary to HTN, arteriosclerosis, or diabetes) compresses the venous wall at a crossing point.

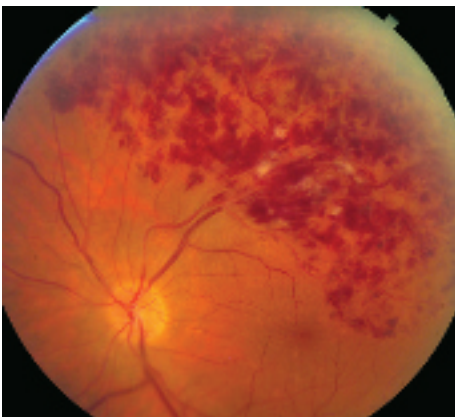


Figure 11.9.1 Branch retinal vein occlusion.

### Workup

1. History: Systemic disease, particularly HTN or diabetes?
2. Complete ocular examination, including dilated retinal examination with indirect ophthalmoscopy to look for retinal neovascularization and ME.
3. OCT: Used to help detect presence and extent of ME as well as monitor response to therapy.
4. Check blood pressure.
5. Blood tests: Fasting blood sugar and hemoglobin A1c, lipid profile, CBC with differential and platelets, PT/PTT. If clinically indicated, consider a more comprehensive workup. See 11.8, CENTRAL RETINAL VEIN OCCLUSION.
6. Medical examination: Performed by an internist to check for cardiovascular disease.
7. An IVFA is obtained after the hemorrhages clear or sooner if neovascularization is suspected.

### Treatment

1. Retinal neovascularization: Sector PRP to the ischemic area, which corresponds to area of capillary nonperfusion on IVFA.
2. Prompt and appropriate treatment of underlying medical conditions (e.g., HTN).

### BRVO-Related Macular Edema

1. Anti-VEGF treatment is now the gold standard. Intravitreal ranibizumab 0.5 mg and aflibercept 2 mg are FDA-approved for treating RVO-associated ME. Intravitreal bevacizumab has also been used off-label. Risks of intravitreal injection are low but include VH and endophthalmitis.
2. Focal retinal laser photocoagulation has historically been the gold-standard treatment if edema is present for 3 to 6 months duration, and visual acuity is below 20/40 with macular capillary perfusion. However, anti-VEGF treatment is now largely favored. Limitations of focal laser include length of time before effect (often several months) and the need to wait until retinal hemorrhages clear.

3. Dexamethasone intravitreal implant or off-label intravitreal steroid (e.g., triamcinolone 40 mg/mL, inject 1 to 4 mg). See 11.8, CENTRAL RETINAL VEIN OCCLUSION.

**NOTE:** There is an evolving trend, particularly in cases of severe edema, to initiate treatment with pharmacologic agents for rapid visual recovery followed by focal laser for better durability of effect. Multiple pharmacologic trials (BRAVO and CRUISE) have validated that early anti-VEGF treatment leads to better visual outcomes.

## Follow Up

In general, every month initially, with gradual interval taper based on vision, presence of ME, and treatment response. At each visit, the patient should be checked for neovascularization and ME.

## REFERENCES

- Campochiaro PA, Heier JS, Feiner L, et al. Ranibizumab for macular edema following branch retinal vein occlusion: six-month primary end point results of a phase III study. *Ophthalmology*. 2010;117(6):1102-1112.
- Varma R, Bressler NM, Suñer I, et al. Improved vision-related function after ranibizumab for macular edema after retinal vein occlusion: results from the BRAVO and CRUISE trials. *Ophthalmology*. 2012;119(10):2108-2118.

## 11.10 Hypertensive Retinopathy

### Symptoms

Usually asymptomatic, although may have decreased vision.

### Signs

(See Figure 11.10.1.)

**Critical.** Generalized or localized retinal arteriolar narrowing, almost always bilateral.

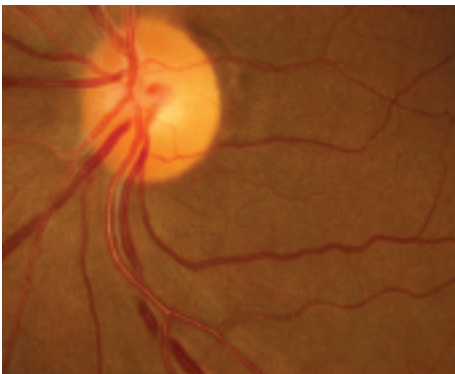
### Other

- Chronic HTN: Arteriovenous crossing changes (“AV nicking”), retinal arteriolar sclerosis

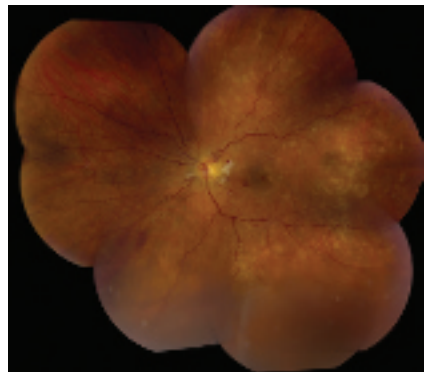
(“copper” or “silver” wiring), CWSs, flame-shaped hemorrhages, arterial macroaneurysms, central or branch occlusion of an artery or vein. Rarely, neovascular complications can develop.

- Acute (“malignant”) HTN or accelerated HTN: Hard exudates often in a “macular star” configuration, retinal edema, CWSs, flame-shaped hemorrhages, optic nerve head edema. Rarely serous RD or VH. Areas of focal chorioretinal atrophy (from previous choroidal infarcts [Elschnig spots]) are a sign of past episodes of acute HTN.

(See Figure 11.10.2.)



**Figure 11.10.1** Chronic hypertensive retinopathy with arteriolar narrowing and arteriovenous nicking.



**Figure 11.10.2** Acute (“malignant”) hypertensive retinopathy.





**NOTE:** When unilateral, suspect carotid artery obstruction on the side of the normal-appearing eye, sparing the retina from the effects of the HTN.

### Differential Diagnosis

- Diabetic retinopathy: Hemorrhages are usually dot-blot and microaneurysms are common; vessel attenuation is less common. See 11.12, DIABETIC RETINOPATHY.
- Collagen vascular disease: May show multiple CWSs, but few to no other fundus findings characteristic of HTN.
- Anemia: Mainly hemorrhage without marked arterial changes.
- Radiation retinopathy: History of irradiation. Most commonly occurs within a few years, but can develop at any time.
- CRVO or BRVO: Unilateral, multiple hemorrhages, venous dilation, and tortuosity. May be the result of HTN. See 11.8, CENTRAL RETINAL VEIN OCCLUSION or 11.9, BRANCH RETINAL VEIN OCCLUSION.

### Etiology

- Primary HTN: No known underlying cause.
- Secondary HTN: Typically the result of pre-eclampsia/eclampsia, pheochromocytoma,

kidney disease, adrenal disease, aortic coarctation, others.

### Workup

1. History: Known HTN, diabetes, or adnexal radiation?
2. Check blood pressure.
3. Complete ocular examination, particularly dilated fundus examination.
4. Refer patient to a medical internist or an emergency department. The urgency depends on the blood pressure reading and whether the patient is symptomatic. A systolic blood pressure  $\geq 180$  mm Hg, a diastolic blood pressure  $\geq 110$  mm Hg or the presence of chest pain, difficulty breathing, headache, change in mental status, or blurred vision with optic disc swelling requires immediate medical attention.
5. Patients may need workup for secondary causes of hypertension such as those listed above.

### Treatment

Control the HTN, as per the internist.

### Follow Up

Every 2 to 3 months at first and then every 6 to 12 months.

## 11.11 Ocular Ischemic Syndrome/Carotid Occlusive Disease

### Symptoms

Decreased vision, ocular or periorbital pain, afterimages or prolonged recovery of vision after exposure to bright light, may have a history of transient monocular visual loss (amaurosis fugax). Usually unilateral, although up to 20% of cases can be bilateral. Typically occurs in patients aged 50 to 80 years. Men outnumber women 2:1.

### Signs

**Critical.** Although retinal veins are dilated and irregular in caliber, they are typically not tortuous. The retinal arterioles are narrowed. Associated findings include midperipheral retinal hemorrhages (80%), iris neovascularization

(66%), neovascularization of the disc (35%), and neovascularization of the retina (8%).

**Other.** External collateral vessels on the forehead, episcleral injection, corneal edema, mild anterior uveitis, neovascular glaucoma, iris atrophy, cataract, retinal microaneurysms, CWSs, spontaneous pulsations of the central retinal artery, and cherry-red spot. CRAO may occur.

### Differential Diagnosis

- CRVO: Diffuse retinal hemorrhages. Dilated and tortuous retinal veins. Decreased vision after exposure to light and orbital pain are not typically found. Ophthalmodynamometry and IVFA may aid in differentiating OIS from

CRVO. See 11.8, CENTRAL RETINAL VEIN OCCLUSION.

- Diabetic retinopathy: Bilateral, usually symmetric. Hard exudates are often present. See 11.12, DIABETIC RETINOPATHY.
- Aortic arch disease: Caused by atherosclerosis, syphilis, or Takayasu arteritis. Produces a clinical picture identical to OIS, but usually bilateral. Examination reveals absent arm and neck pulses, cold hands, and arm muscle spasms with exercise.

### Etiology

- Ipsilateral carotid artery disease: Usually  $\geq 90\%$  stenosis.
- Ipsilateral ophthalmic artery disease: Less common.
- Ipsilateral central retinal artery obstruction: Rare.
- Giant cell arteritis: Rare.

### Workup

1. History: Previous episodes of transient monocular visual loss? Cold hands or arm muscle spasms with exercise?
2. Complete ocular examination: Search carefully for anterior chamber flare, asymmetric cataract, and NVI/NVA/NVD/NVE.
3. Medical examination: Evaluate for HTN, diabetes, and atherosclerotic disease. Check pulses. Cardiac and carotid auscultation.

4. Laboratory workup for GCA in the appropriate settings. See 10.17, GIANT CELL ARTERITIS.
5. Consider IVFA for diagnostic purposes.
6. Noninvasive carotid artery evaluation: Duplex Doppler US, oculoplethysmography, magnetic resonance angiography, others.
7. Consider orbital color Doppler US.
8. Consider ophthalmodynamometry if CRVO diagnosis cannot be excluded.
9. Carotid arteriography is reserved for patients in whom surgery is to be performed.
10. Consider cardiology consultation, given the high association with cardiac disease.

### Treatment

1. Carotid endarterectomy for significant stenosis. Refer to neurovascular surgeon.
2. Consider PRP and anti-VEGF agents in the presence of neovascularization.
3. Manage glaucoma if present. See 9.14, NEOVASCULAR GLAUCOMA.
4. Control HTN, diabetes, and cholesterol. Refer to internist.
5. Lifestyle modification (e.g., smoking cessation).

### Follow Up

Depends on the age, general health of the patient, and the symptoms and signs of disease. Surgical candidates should be evaluated urgently.

## 11.12 Diabetic Retinopathy

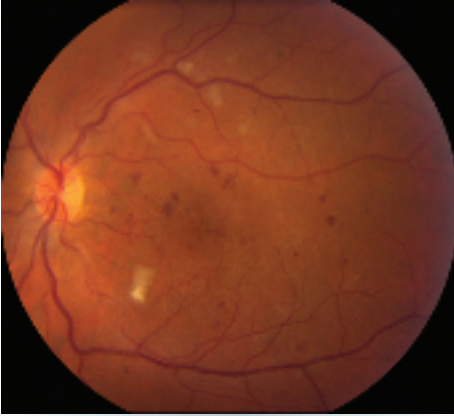
### Diabetic Retinopathy Disease Severity Scale

- No apparent retinopathy.
- Mild nonproliferative diabetic retinopathy (NPDR): Microaneurysms only.
- Moderate NPDR: More than mild NPDR, but less than severe NPDR (see Figure 11.12.1). May have CWSs and venous beading.
- Severe NPDR: Any of the following in the absence of PDR: Diffuse (traditionally  $>20$ ) intraretinal hemorrhages in all four quadrants, two quadrants of venous beading, or one quadrant of prominent intraretinal microvascular abnormalities (see Figure 11.12.2).

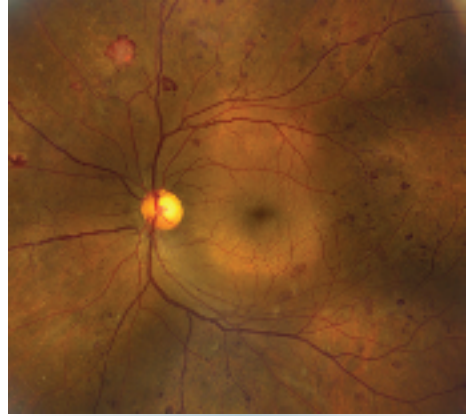
- PDR: Neovascularization of one or more of the following: iris, angle, optic disc, or elsewhere in retina; or vitreous/preretinal hemorrhage (see Figures 11.12.3 and 11.12.4).
- Diabetic macular edema (DME): May be present in any of the stages listed above. DME affecting or threatening the fovea is an indication for treatment (see Figures 11.12.5 and 11.12.6).

### Differential Diagnosis for Nonproliferative Diabetic Retinopathy

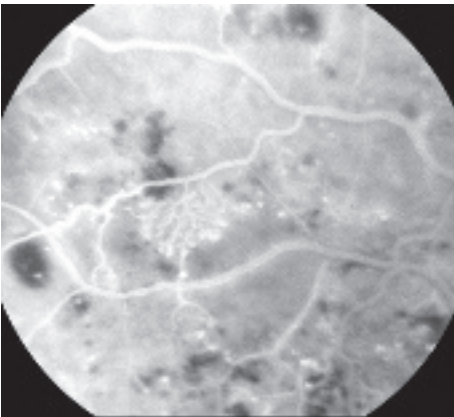
- CRVO: Optic disc swelling, veins are more dilated and tortuous, hard exudates and microaneurysms usually not found,



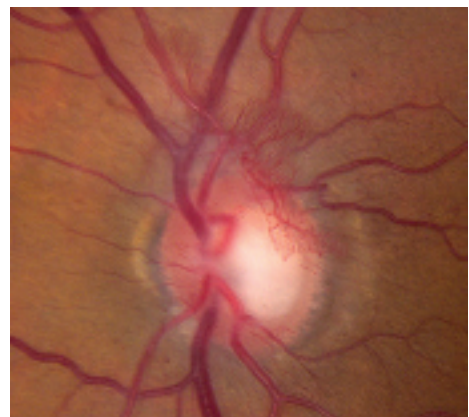**Figure 11.12.1** Moderate nonproliferative diabetic retinopathy with microaneurysms and cotton-wool spots.



**Figure 11.12.3** Proliferative diabetic retinopathy with neovascularization and scattered microaneurysms.



**Figure 11.12.2** Intravenous fluorescein angiography of intraretinal microvascular abnormality.



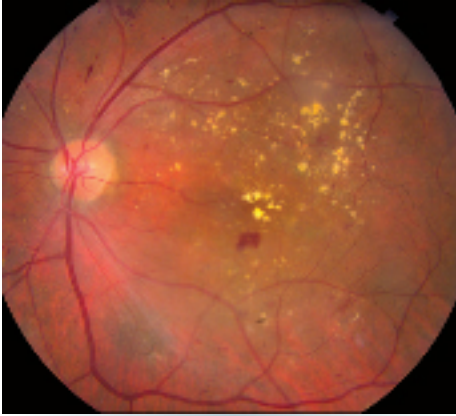**Figure 11.12.4** Proliferative diabetic retinopathy with neovascularization of the optic disc.

hemorrhages are nearly always in the NFL (“splinter hemorrhages”). CRVO is generally unilateral and of more sudden onset. See 11.8, CENTRAL RETINAL VEIN OCCLUSION.

- BRVO: Hemorrhages are distributed along a vein and do not cross the horizontal raphe (midline). See 11.9, BRANCH RETINAL VEIN OCCLUSION.
- OIS: Hemorrhages mostly in the midperiphery and larger; exudates are absent. Usually accompanied by pain; mild anterior chamber reaction; corneal edema; episcleral vascular

congestion; a mid-dilated, poorly reactive pupil; iris neovascularization. See 11.11, OCULAR ISCHEMIC SYNDROME/CAROTID OCCLUSIVE DISEASE.

- Hypertensive retinopathy: Hemorrhages fewer and typically flame-shaped, microaneurysms rare, and arteriolar narrowing present often with arteriovenous crossing changes (“AV nicking”). See 11.10, HYPERTENSIVE RETINOPATHY.
- Radiation retinopathy: Usually develops within a few years of radiation. Microaneurysms are rarely present. See 11.5, COTTON-WOOL SPOT.



**Figure 11.12.5** Nonproliferative diabetic retinopathy with clinically significant macular edema.

### Differential Diagnosis for Proliferative Diabetic Retinopathy

- Neovascular complications of CRAO, CRVO, or BRVO: See specific sections.
- Sick cell retinopathy: Peripheral retinal neovascularization. “Sea fans” of neovascularization present. See 11.20, SICKLE CELL RETINOPATHY (INCLUDING SICKLE CELL DISEASE, ANEMIA, AND TRAIT).
- Embolization from intravenous drug abuse (talc retinopathy): Peripheral retinal neovascularization in patient with history of intravenous drug abuse. Typically see talc particles in retinal vessels. See 11.33, CRYSTALLINE RETINOPATHY.
- Sarcoidosis: May have uveitis, exudates around veins (“candle-wax drippings”), NVE, or systemic findings. See 12.6, SARCOIDOSIS.
- Other inflammatory syndromes (e.g., systemic lupus erythematosus).
- OIS: See 11.11, OCULAR ISCHEMIC SYNDROME/CAROTID OCCLUSIVE DISEASE.
- Radiation retinopathy: See above.
- Hypercoagulable states (e.g., antiphospholipid syndrome).

### Workup

1. Slit lamp examination using gonioscopy with careful attention for NVI and NVA, preferably before pharmacologic dilation.

2. Dilated fundus examination by using a 90- or 60-diopter or fundus contact lens with a slit lamp to rule out neovascularization and ME. Use indirect ophthalmoscopy to examine the retinal periphery.
3. Check fasting blood sugar, hemoglobin A1c, and lipid panel.
4. Check blood pressure.
5. Consider IVFA to determine areas of perfusion abnormalities, foveal ischemia, microaneurysms, and subclinical neovascularization, especially if considering focal macular laser therapy.
6. Consider OCT to evaluate for presence and extent of DME. OCT angiography (OCTA) can be useful to check for presence of significant central macular ischemia.

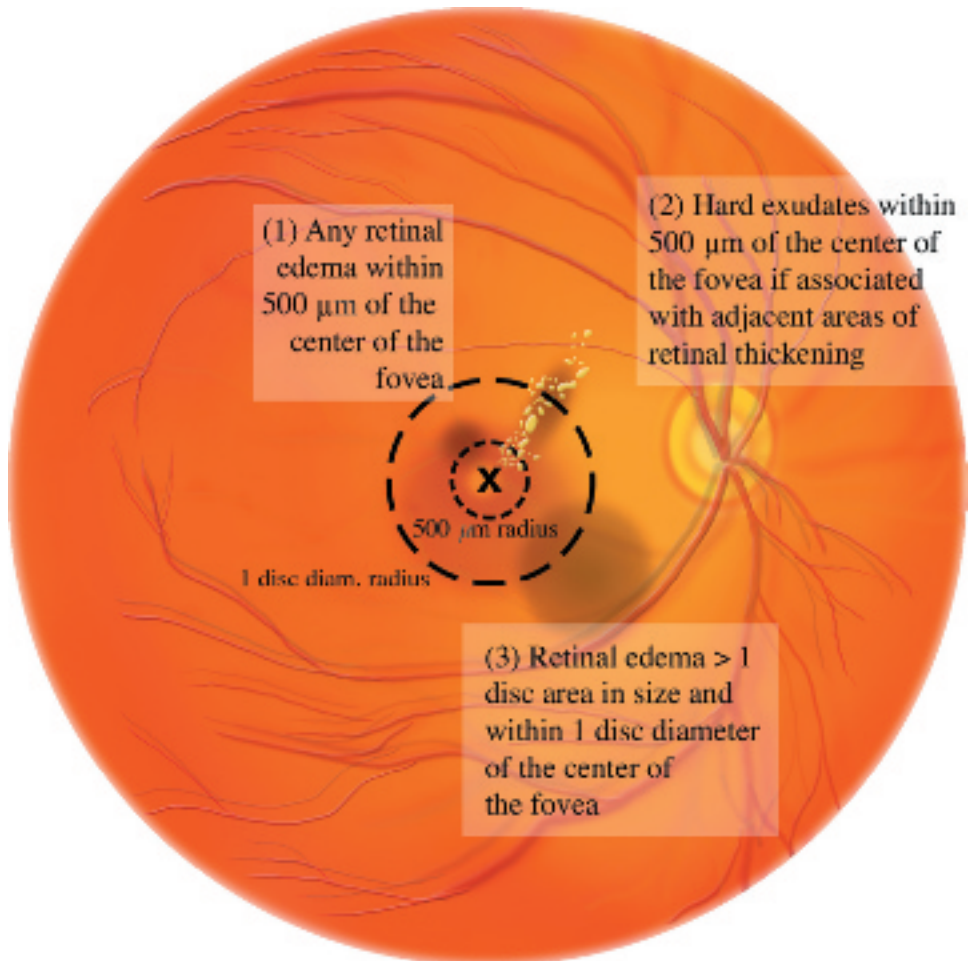
### Treatment

#### Diabetic Macular Edema

1. Anti-VEGF agents (FDA-approved ranibizumab and aflibercept, as well as off-label bevacizumab) are first-line therapy for center-involving DME.
2. Those patients who have a suboptimal response to these anti-VEGF agents or require ongoing, frequent anti-VEGF therapy can consider intravitreal corticosteroid therapy with FDA-approved dexamethasone or long-acting fluocinolone acetonide injectable implants. Off-label intravitreal corticosteroid (e.g., triamcinolone 40 mg/mL, injecting 1 to 4 mg) can also be considered. Complications include cataract formation and elevated IOP.
3. Focal macular laser treatment can be considered in patients with extrafoveal microaneurysms causing significant edema. Macular laser can also be considered in patients for whom anti-VEGF and intravitreal steroid injections are contraindicated. Most practitioners avoid using anti-VEGF agents in pregnant patients, though no study has definitively shown adverse fetal side effects.

#### Proliferative Diabetic Retinopathy

1. PRP is indicated for any one of the following high-risk characteristics (see Figure 11.12.7):
  - NVD greater than one-fourth to one-third of the disc area in size.



**Figure 11.12.6** Clinically significant macular edema.

- Any degree of NVD when associated with preretinal hemorrhage or VH.
  - NVE greater than one-half of the disc area in size when associated with preretinal hemorrhage or VH.
  - Any NVI or NVA.
2. Anti-VEGF therapy can be utilized for PDR as an alternative to PRP and is the preferred initial therapy in the presence of DME or if the view to the peripheral retina is limited by VH. Anti-VEGF therapy without PRP should be utilized cautiously, as patients lost

to follow up have been shown to have worse anatomic and visual outcomes.



**NOTE:** Some physicians treat NVE or any degree of NVD without preretinal hemorrhage or VH, especially in unreliable patients.

### *Indications for Vitrectomy*

Vitrectomy may be indicated for any one of the following conditions:

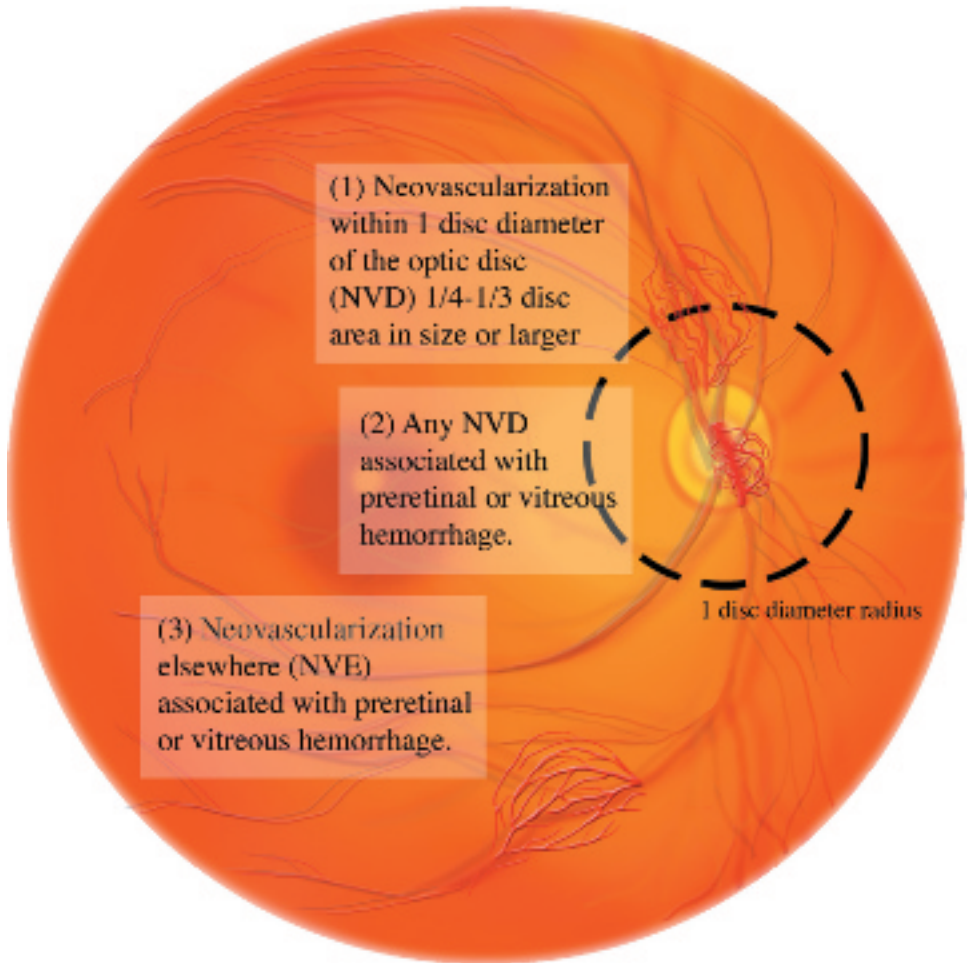


Figure 11.12.7 High-risk characteristics for diabetic retinopathy.

1. Dense, nonclearing or recurrent VH causing significant decreased vision.
2. Traction RD involving and progressing within the macula.
3. Macular epiretinal membranes (ERMs) or vitreomacular traction causing significant visual symptoms.
4. Dense premacular hemorrhage.
5. Chronic DME not responsive to other treatment.
6. Severe retinal neovascularization and fibrous proliferation that is unresponsive to laser photocoagulation or anti-VEGF therapy.



**NOTE:** Young patients with type 1 diabetes are known to have more aggressive PDR and therefore may benefit from earlier vitrectomy, laser photocoagulation, or anti-VEGF therapy. B-scan US may be required to rule out tractional detachment of the macula in eyes with dense VH obscuring a fundus view.


**Follow Up**

1. Diabetes without retinopathy. Annual dilated examination.
2. Mild NPDR. Dilated examination every 6 to 9 months.

**TABLE 11.12.1** Recommendations Based on the Baseline Diabetic Retinopathy in Pregnancy

| Baseline Diabetic Retinopathy | Gestational Diabetes   | None or Minimal Nonproliferative Diabetic Retinopathy (NPDR)                               | Mild-to-Moderate NPDR                                      | High-Risk NPDR   | Proliferative Diabetic Retinopathy (PDR)   |
|-------------------------------|------------------------|--|--|--|--|
| Gestational course            | No risk of retinopathy | No progression in vast majority. Of those who progress, only a few have visual impairment. | Progression in up to 50%. Postpartum regression in many.   | Progression in up to 50%. Postpartum regression in some.   | Tends to progress rapidly.   |
| Eye examinations              | None                   | First and third trimester  | Every trimester  | Monthly  | Monthly  |
| Treatment                     | None                   | None   | None, unless high-risk proliferative retinopathy develops. | None, unless high-risk proliferative retinopathy develops. | Treat PDR with panretinal photocoagulation. Observe diabetic macular edema (high rate of spontaneous postpartum regression). |

- Moderate to severe NPDR. Dilated examination every 4 to 6 months.
- PDR (not meeting high-risk criteria). Dilated examination every 2 to 3 months.
- Diabetes and pregnancy. Changes that occur during pregnancy have a high likelihood of postpartum regression. See **Table 11.12.1** for follow-up recommendations.

 **NOTE:** The Diabetes Control and Complications Trial showed that strict control of blood sugar with insulin (in type 1 diabetes) decreases the progression of diabetic retinopathy, as well as nephropathy and neuropathy.

## REFERENCES

- Wilkinson CP, Ferris FL III, Klein RE, et al. Proposed international clinical diabetic retinopathy and diabetic macular edema disease severity scales. *Ophthalmology*. 2003;110:1677-1682.
- Mitchell P, Bandello F, Schmidt-Erfurth U, et al. The RESTORE Study ranibizumab monotherapy or combined with laser versus laser monotherapy for diabetic macular edema. *Ophthalmology*. 2011;118:615-625.
- Korobelnik JF, Do DV, Schmidt-Erfurth U, et al. Intravitreal aflibercept for diabetic macular edema. *Ophthalmology*. 2014;121(11):2247-2254.
- Boyer DS, Yoon YH, Belfort R Jr, et al. Three-year, randomized, sham-controlled trial of dexamethasone intravitreal implant in patients with diabetic macular edema. *Ophthalmology*. 2014;121(10):1904-1914.
- Cunha-Vaz J, Ashton P, Iezzi R, et al. Sustained delivery fluocinolone acetonide vitreous implants: long-term benefit in patients with chronic diabetic macular edema. *Ophthalmology*. 2014;121(10):1892-1903.
- Diabetic Retinopathy Clinical Research Network. Panretinal photocoagulation vs intravitreal ranibizumab for proliferative diabetic retinopathy: a randomized trial. *J Am Med Assoc*. 2015;314(20):2137-2146.
- Obeid A, Su D, Patel SN, et al. Outcomes of eyes lost to follow-up with proliferative diabetic retinopathy that received panretinal photocoagulation versus intravitreal anti-vascular endothelial growth factor. *Ophthalmology*. 2019;126(3):407-413.



## 11.13 Vitreous Hemorrhage

### Symptoms

Sudden, painless loss of vision or sudden appearance of black spots, cobwebs, or haze in the vision.

### Signs

(See Figure 11.13.1.)

**Critical.** In severe VH, the red fundus reflex may be absent, and there may be limited or no view to the fundus. Red blood cells may be seen in the anterior vitreous (or anterior chamber). In mild VH, there may be a partially obscured view to the fundus. Chronic VH has a yellow ocher appearance from hemoglobin breakdown.

**Other.** A mild RAPD is possible in the setting of dense hemorrhage. Depending on the etiology, there may be other fundus abnormalities.

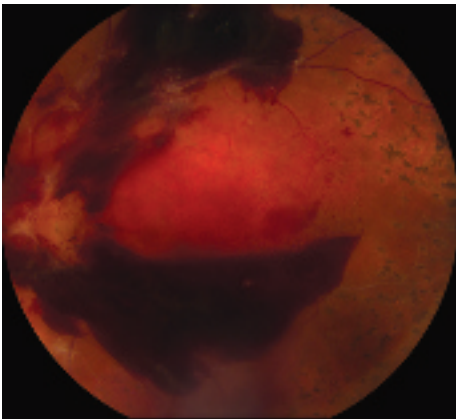
### Differential Diagnosis

- Vitritis (white blood cells in the vitreous): Usually not sudden onset; anterior or posterior uveitis may also be present. No red blood cells are seen in the vitreous. See 12.3, POSTERIOR UVEITIS.
- RD: May occur without a VH, but the symptoms may be similar. In VH due to RD, the peripheral retina may be obscured on

indirect ophthalmoscopy requiring B-scan US to detect the detachment. See 11.3, RETINAL DETACHMENT.

### Etiology


- Diabetic retinopathy: Usually history of diabetes with diabetic retinopathy. Diabetic retinopathy is usually evident in the contralateral eye. In VH due to PDR, the peripheral retina is often visible on indirect ophthalmoscopy. See 11.12, DIABETIC RETINOPATHY.
- PVD: Common in middle-aged or elderly patients. Usually patients note floaters and flashing lights. See 11.1, POSTERIOR VITREOUS DETACHMENT.
- Retinal break: Commonly superior in cases of dense VH. This may be demonstrated by scleral depression and, if poor view, B-scan US. See 11.2, RETINAL BREAK.
- RD: May be diagnosed by B-scan US if the retina cannot be viewed on clinical examination. See 11.3, RETINAL DETACHMENT.
- Retinal vein occlusion (usually a BRVO): Commonly occurs in older patients with a history of high blood pressure. See 11.9, BRANCH RETINAL VEIN OCCLUSION.
- Exudative age-related macular degeneration (AMD): Usually with advanced CNV. Poor vision before the VH as a result of the underlying macular disease. Macular drusen and/or other findings of AMD are found in the contralateral eye. B-scan US may aid in the diagnosis. See 11.17, NEOVASCULAR OR EXUDATIVE (WET) AGE-RELATED MACULAR DEGENERATION.
- Sickle cell disease: May have peripheral retinal neovascularization in the contralateral eye, typically in a “sea fan” configuration and salmon color. See 11.20, SICKLE CELL RETINOPATHY (INCLUDING SICKLE CELL DISEASE, ANEMIA, AND TRAIT).
- Trauma: By history.
- Valsalva: By history.
- Intraocular tumor: May be visible on ophthalmoscopy or B-scan US. See 5.13, MALIGNANT MELANOMA OF THE IRIS and 11.36, CHOROIDAL NEVUS AND MALIGNANT MELANOMA OF THE CHOROID.



**Figure 11.13.1** Vitreous and preretinal hemorrhage due to proliferative diabetic retinopathy.



- Subarachnoid or subdural hemorrhage (Terson syndrome): Frequently bilateral pre-retinal or VHS may occur. A severe headache usually precedes the fundus findings. Coma may occur.
- Others: Ruptured arterial macroaneurysm, Eales Disease, Coats disease, retinopathy of prematurity, retinal capillary angiomas of von Hippel-Lindau syndrome, congenital prepapillary vascular loop, retinal cavernous hemangioma, HTN, radiation retinopathy, anterior segment hemorrhage because of an intraocular lens, bleeding diathesis, hematologic malignancy, etc. See specific sections.

 **NOTE:** In infancy and childhood, consider birth trauma, child abuse (e.g., shaken baby syndrome), congenital X-linked retinoschisis, pars planitis, bleeding dyscrasias, and hematologic malignancies.

### Workup

1. History: Any ocular or systemic diseases? Trauma?
2. Complete ocular examination, including slit lamp examination with undilated pupils to check for iris neovascularization, IOP measurement, and dilated fundus examination of both eyes by using indirect ophthalmoscopy. In cases of spontaneous VH, scleral depression is performed if a retinal view can be obtained.
3. When no retinal view can be obtained, B-scan US is performed to detect an associated RD or intraocular tumor. Flap RTs may be detected with scleral depression and may be seen on B-scan US (elevated flap).
4. IVFA may aid in defining the etiology, although the quality of the angiogram depends on the density of the hemorrhage. Additionally, it may be useful to highlight abnormalities in the contralateral eye.

### Treatment

1. If the etiology of VH is not known and a retinal break or an RD or both cannot be ruled out (i.e., there is no known history of one of the diseases mentioned previously, there are no changes in the contralateral eye, and the fundus is obscured by a total VH), close observation versus vitrectomy are options.
2. Observation:
  - No heavy lifting, no straining, no bending. Keep head of bed elevated. This reduces the chance of recurrent bleeding and allows blood to settle inferiorly, permitting a view of the superior peripheral fundus, a common site for possible retinal breaks.
  - Eliminate aspirin, nonsteroidal anti-inflammatory drugs (NSAIDs), and other anticlotting agents unless medically necessary.
  - The underlying etiology is treated as soon as possible (e.g., retinal breaks are sealed with cryotherapy or laser photocoagulation, detached retinas are repaired, and proliferative retinal vascular diseases are treated with anti-VEGF therapy or laser photocoagulation).
3. Vitrectomy:
  - VH accompanied by RD or RT on B-scan US.
  - Nonclearing VH. Because two-thirds of patients with an idiopathic, fundus-obscuring hemorrhage will have RTs or an RD, early vitrectomy should be considered.
  - VH with neovascularization of the iris.
  - Hemolytic or ghost cell glaucoma.

### Follow Up

If observation is elected, the patient is evaluated daily for the first 2 to 3 days. If a total, dense VH persists, and the etiology remains unknown, vitrectomy should be considered.

## 11.14 Cystoid Macular Edema

### Symptoms

Decreased vision.

### Signs

(See Figures 11.14.1 to 11.14.3.)

**Critical.** Irregularity and blunting of the foveal light reflex, macular thickening with or without small intraretinal cysts in the foveal region.

**Other.** Vitreous cells, optic nerve swelling, and dot hemorrhages may be observed depending upon etiology of CME.

### Etiology

- Postoperative, following any ocular surgery, including laser photocoagulation and cryotherapy. The peak incidence of post cataract extraction CME, or Irvine–Gass, is approximately 6 to 10 weeks; the incidence increases with cataract surgical complications including vitreous loss, vitreous to the corneoscleral wound, iris prolapse, or uveal incarceration.
- Diabetic retinopathy: See 11.12, DIABETIC RETINOPATHY.
- CRVO and BRVO: See 11.8, CENTRAL RETINAL VEIN OCCLUSION and 11.9, BRANCH RETINAL VEIN OCCLUSION.
- Uveitis: Particularly pars planitis; see 12.2, INTERMEDIATE UVEITIS.
- Retinitis pigmentosa (RP): See 11.28, RETINITIS PIGMENTOSA AND INHERITED CHORIORETINAL DYSTROPHIES.
- Topical drops: Epinephrine, dipivefrin, and prostaglandin analogs, especially in patients who have undergone cataract surgery.
- Retinal vasculitis: Eales disease, Behçet syndrome, sarcoidosis, necrotizing angiitis, multiple sclerosis, cytomegalovirus retinitis, others.
- Retinal telangiectasias: Coats disease, idiopathic macular telangiectasia, others.
- AMD: See 11.16, NONEXUDATIVE (DRY) AGE-RELATED MACULAR DEGENERATION and 11.17, NEOVASCULAR OR EXUDATIVE (WET) AGE-RELATED MACULAR DEGENERATION.
- ERM: See 11.26, EPIRETINAL MEMBRANE (MACULAR PUCKER, SURFACE-WRINKLING RETINOPATHY, CELLOPHANE MACULOPATHY).
- Associated with other ocular conditions: RD, subfoveal CNV, intraocular tumors, others.
- Others: Systemic HTN, collagen vascular disease, autosomal dominant CME, others.
- Pseudo-CME (no leakage on IVFA): Nicotinic acid maculopathy (typically seen only with relatively high doses of nicotinic acid), taxane drugs, X-linked retinoschisis (can see leakage with ICGA), myopic foveal schisis, Goldmann–Favre disease (and other NR2E3-related retinopathies), pseudohole from an ERM.

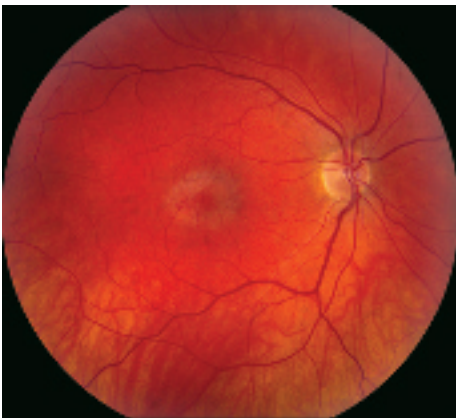

Figure 11.14.1 Cystoid macular edema.

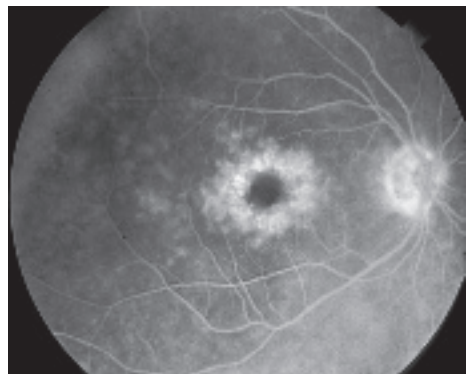


Figure 11.14.2 Intravenous fluorescein angiography of cystoid macular edema.

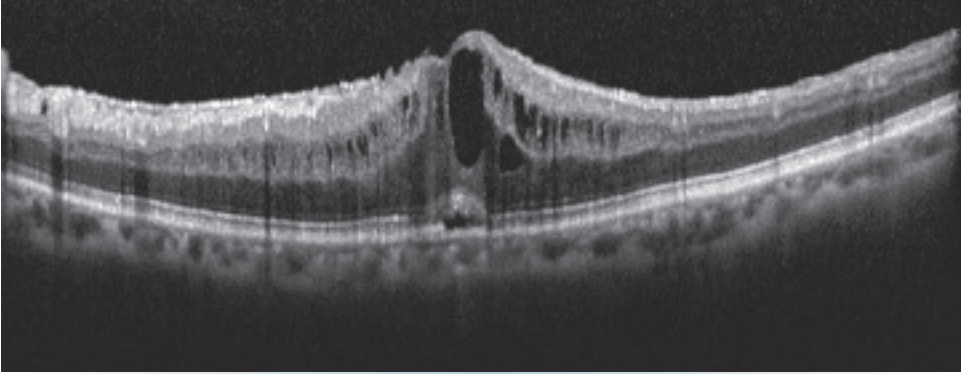


Figure 11.14.3 Optical coherence tomography of cystoid macular edema.

## Workup

1. History: Recent intraocular surgery? Diabetes? Previous uveitis or ocular inflammation? Night blindness or family history of eye disease? Medications, including topical epinephrine, dipivefrin, or prostaglandin analogs?
2. Complete ocular examination, including gonioscopy to rule out the presence of retained lens fragments following cataract surgery and haptic malposition of implanted anterior chamber intraocular lens. Thorough peripheral fundus evaluation (scleral depression inferiorly may be required to detect pars planitis). Macular examination is best performed with a slit lamp and a 60- or 90-diopter lens, fundus contact lens, or a Hruby lens.
3. IVFA shows early leakage of perifoveal capillaries and late macular staining, classically in a petaloid or spoke-wheel pattern. Optic nerve head leakage is sometimes observed (Irvine–Gass syndrome). Fluorescein leakage does not occur in select cases of pseudo-CME (see above).
4. OCT can be utilized to document the presence of CME and demonstrate the efficacy of therapy. OCT outlines the loss of foveal contour resulting from enlarged cystic spaces within the retina and thickening of the macula.
5. Other diagnostic tests when indicated: Fasting blood sugar and hemoglobin A1c, ERG, others.

**NOTE:** Subclinical CME commonly develops after cataract extraction and is noted on IVFA (angiographic CME). OCT shows no CME and these cases are not treated.

## Treatment

Treat the underlying disorder if possible. For CME related to specific etiologies (e.g., diabetes, retinal vein occlusion, intermediate uveitis, etc.), see specific sections.

1. Topical NSAID (e.g., ketorolac 0.5% q.i.d., bromfenac 0.09%, or nepafenac 0.3% daily) often in conjunction with topical steroids (e.g., prednisolone acetate 1% q.i.d.).
2. Discontinue topical epinephrine, dipivefrin, or prostaglandin analog drops and medications containing nicotinic acid.
3. Other forms of therapy are often used to treat CME depending upon etiology:
  - Subtenon steroid (e.g., triamcinolone 40 mg/mL, inject 0.5 to 1.0 mL).
  - Intravitreal steroid (e.g., triamcinolone 40 mg/mL, inject 1 to 4 mg).
  - Intravitreal anti-VEGF therapy (e.g., bevacizumab 1.25 mg in 0.05 mL).
  - Systemic steroids (e.g., prednisone 40 mg p.o. daily for 5 days and then taper over 2 weeks).
  - Systemic NSAIDs (e.g., indomethacin 25 mg p.o. t.i.d. for 6 weeks).
  - Topical or systemic carbonic anhydrase inhibitors (e.g., dorzolamide 2% t.i.d. or acetazolamide 500 mg p.o. daily starting dose) in cases of RP-associated CME.
  - CME with or without vitreous incarceration in a surgical wound may be improved by vitrectomy or YAG laser lysis of the vitreous strand.

**Follow Up**

Postsurgical CME patients should be started on a topical NSAID and a topical steroid with follow

up in 4 to 6 weeks to determine response to topical drop therapy. Other forms of CME should be followed in a similar time frame to monitor response to initial therapy.

**11.15 Central Serous Chorioretinopathy****Symptoms**

Central scotoma, blurred or dim vision, objects may appear distorted (metamorphopsia) and miniaturized (micropsia), colors may appear faded. Usually unilateral, but can be bilateral (more likely in older patients, may not be symptomatic at the same time). May be asymptomatic.

**Signs**

(See Figure 11.15.1.)

**Critical.** Localized serous detachment of the neurosensory retina in the macula without subretinal blood or lipid exudates. The margins of the detachment are sloping and merge gradually into the attached retina.

**Other.** Visual acuity usually ranges from 20/20 to 20/200. Amsler grid testing reveals relative scotoma and distortion of straight lines. May have a small RAPD, serous RPE detachment, or deposition of subretinal fibrin. Focal RPE changes may indicate sites of previous episodes.

**Differential Diagnosis**

These entities may produce a serous detachment of the neurosensory retina in the macula

- AMD: Patient usually  $\geq 50$  years old, drusen, pigment epithelial alterations, may have choroidal (subretinal) neovascularization, often bilateral. See 11.16, NONEXUDATIVE (DRY) AGE-RELATED MACULAR DEGENERATION and 11.17, NEOVASCULAR OR EXUDATIVE (WET) AGE-RELATED MACULAR DEGENERATION.
- Optic pit: The optic disc has a small defect (a pit) in the nerve tissue. A serous RD may be present, contiguous with the optic disc. See 11.34, OPTIC PIT.
- Macular detachment as a result of an RRD or macular hole: In RRD, a hole in the retina can be found. See 11.3, RETINAL DETACHMENT and 11.25, VITREOMACULAR ADHESION (VMA)/VITREOMACULAR TRACTION (VMT)/MACULAR HOLE.
- Choroidal tumor, particularly choroidal hemangioma: See 11.36, CHOROIDAL NEVUS AND MALIGNANT MELANOMA OF THE CHOROID.
- Hypertension: See 11.10, HYPERTENSIVE RETINOPATHY.
- Pigment epithelial detachment (PED): The margins of a PED are more distinct than those of CSCR, and the RPE is elevated. Occasionally, PED may accompany CSCR or AMD.
- Others: Idiopathic choroidal effusion, inflammatory choroidal disorders, and chronic renal failure.

**Etiology**

- Idiopathic: Most common in young adult to middle-aged men. In women, CSCR has an association with pregnancy. Increased incidence in patients with lupus.
- Increased endogenous cortisol: This might explain a possible association with psychological or physiologic stress (type A personality). Rare cases exist with cortisol producing adrenal adenomas or Cushing syndrome.
- Exogenous cortisol: Corticosteroid use, including nasal corticosteroid sprays and topical creams.

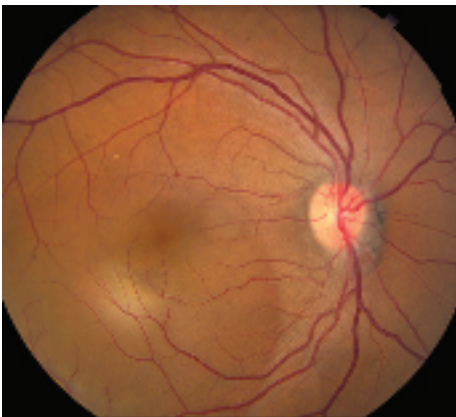
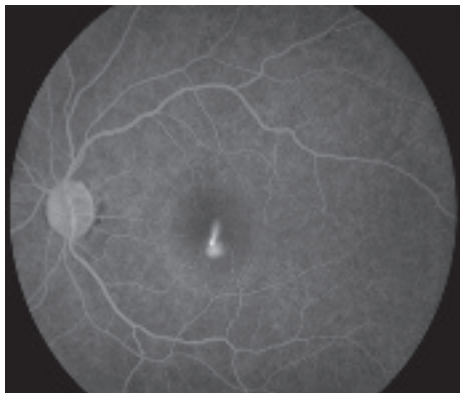


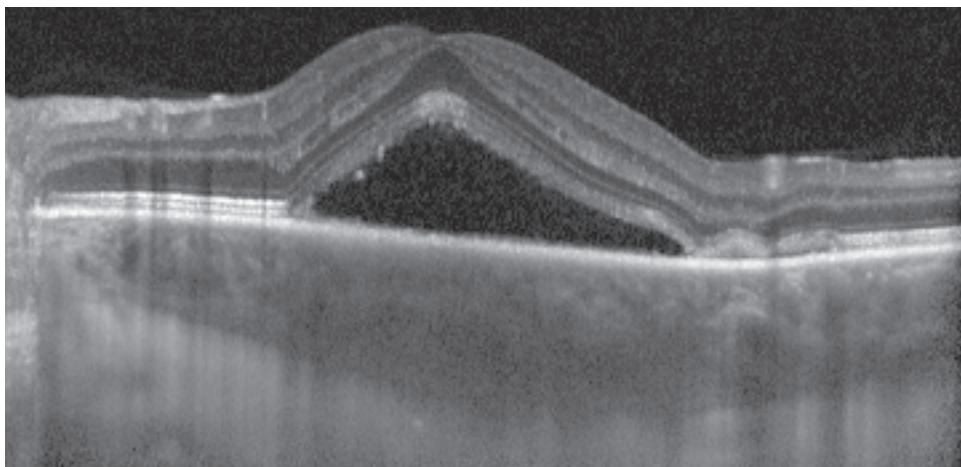
Figure 11.15.1 Central serous chorioretinopathy.



**Figure 11.15.2** Intravenous fluorescein angiography of central serous chorioretinopathy showing “smoke-stack” pattern of dye leakage.

### Workup

1. Amsler grid test to document the area of field involved. See Appendix 4, AMSLER GRID.
2. Slit lamp examination of the macula with a fundus contact, Hruby, or 60- or 90-diopter lens to rule out concomitant CNV. In addition, search for an optic pit of the disc.
3. Dilated fundus examination with indirect ophthalmoscopy to rule out a choroidal tumor or RRD.
4. OCT is helpful in demonstrating subretinal fluid or PEDs and for monitoring purposes. Enhanced-depth imaging OCT often



**Figure 11.15.3** Enhanced-depth imaging optical coherence tomography of central serous chorioretinopathy showing subretinal fluid and choroidal thickening.

demonstrates choroidal thickening and may be a useful adjunct in diagnosis (see **Figures 11.15.2** and **11.15.3**).

5. IVFA and ICGA if the diagnosis is uncertain or presentation atypical, CNV is suspected, or laser treatment is to be considered. IVFA shows the nearly pathognomonic “smoke-stack” pattern of dye leakage in 10% to 20% of cases. ICGA shows choroidal artery and choriocapillaris filling delays and characteristic multifocal hyperfluorescent patches in the early phase.
6. In cases of chronic CSCR, a systemic workup including cortisol levels and renal function should be considered.

### Treatment

1. Observation: Acute CSCR is usually self-limited with good visual prognosis. Worse prognosis for patients with recurrent disease, multiple areas of detachment, or prolonged course.
2. Stop corticosteroids, if possible, including topical skin and nasal spray preparations.
3. Laser photocoagulation: May accelerate visual recovery, but long-term benefit and safety are unclear. May increase risk of CNV formation. Given the CNV risk, use low laser intensity. Consider laser for:
  - Persistence of a serous detachment for several months.
  - Recurrence of the condition in an eye that sustained a permanent visual deficit from a previous episode.

- Occurrence in the contralateral eye after a permanent visual deficit resulted from a previous episode.
  - Patient requires prompt restoration of vision (e.g., occupational necessity).
4. Photodynamic therapy (PDT): May be helpful for chronic CSCR. Half-dose PDT may be considered for rapid SRF resolution in patients with acute CSCR.
  5. Mineralocorticoid receptor antagonists: Eplerenone and spironolactone have been associated with improved anatomic and visual outcomes in chronic CSCR.
  6. If CNV develops, consider anti-VEGF therapy.

### Follow Up

1. Examine patients every 6 to 8 weeks until resolution.

## 11.16 Nonexudative (Dry) Age-Related Macular Degeneration

### Symptoms

Gradual loss of central vision, Amsler grid changes; may be asymptomatic.

### Signs

(See Figures 11.16.1 and 11.16.2.)

**Critical.** Macular drusen, clumps of pigment in the outer retina, and RPE atrophy, almost always in both eyes.

**Other.** Confluent retinal and choriocapillaris atrophy (e.g., geographic atrophy), dystrophic calcification.

### Differential Diagnosis

- Peripheral drusen: Drusen only located outside of the macular area.

- Myopic degeneration: Characteristic peripapillary changes and macular changes without drusen. See 11.22, HIGH MYOPIA.
- CSCR: Serous retinal elevation, RPE detachments, and mottled RPE, without drusen, hemorrhage, or exudate, usually in patients <50 years of age. See 11.15, CENTRAL SEROUS CHORIORETINOPATHY.
- Inherited central retinal dystrophies: Stargardt disease, pattern dystrophy, Best disease, others. Variable macular pigmentary changes, atrophy, or accumulation of lipofuscin or a combination of these. Usually <50 years, without drusen, familial occurrence. See specific entities.
- Toxic retinopathies (e.g., chloroquine toxicity): Mottled hypopigmentation with ring of hyperpigmentation (bull's eye maculopathy) without drusen. Possible history of drug ingestion or exposure.

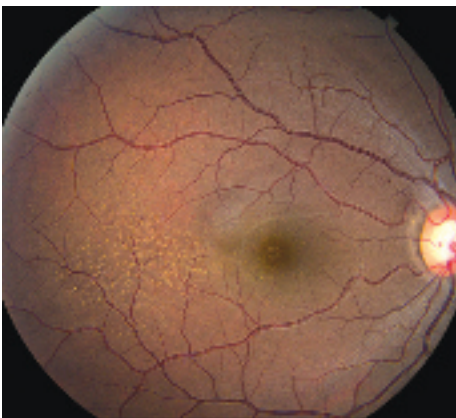

Figure 11.16.1 Dry AMD with fine drusen.

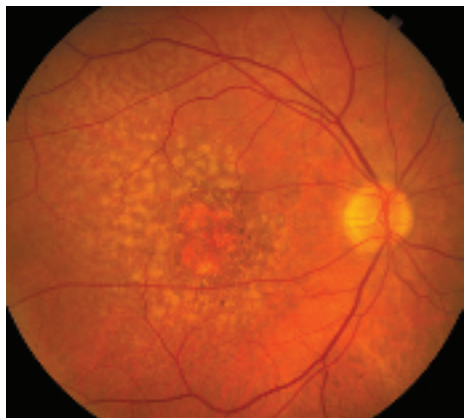


Figure 11.16.2 Dry AMD with soft drusen.

- Inflammatory maculopathies: Multifocal choroiditis, rubella, serpiginous choroidopathy, and others. Variable chorioretinal atrophy, often with vitreous cells and without drusen. See specific entities.

### Workup

1. History: Presence of risk factors (e.g., family history, smoking)? See risk factors for loss of vision, 11.17, NEOVASCULAR OR EXUDATIVE (WET) AGE-RELATED MACULAR DEGENERATION.
2. Amsler grid or preferential hyperacuity perimetry (PHP) testing at home to detect central or paracentral scotoma potentially indicative of neovascular transformation. See Appendix 4, AMSLER GRID.
3. Macular examination with a 60- or 90-diopter or a fundus contact lens: Look for risk factors for conversion to the exudative form, such as soft drusen or pigment clumping. Look for geographic atrophy. Look for signs of the exudative form such as edema, SRF, lipid exudation, or hemorrhage (disappearance of drusen may herald the development of CNV).
4. Baseline and periodic FAF may be useful to monitor for progression, particularly geographic atrophy.
5. IVFA or OCT when exudative AMD is suspected based on subjective or objective change in vision or examination findings. Drusen and RPE atrophy are often more visible on IVFA and FAF. OCTA is also a potentially useful diagnostic test as a noninvasive substitute for IVFA or if IVFA is inconclusive, especially with masquerade conditions such as pattern dystrophy or CSCR.

### Treatment

Patients with intermediate dry AMD (one large druse [125 microns] and/or  $\geq 20$  medium drusen [63 to 125 microns]), or advanced dry or exudative AMD in one eye but not the other eye, are at high risk for development of advanced stages of AMD. The original Age-Related Eye Disease Study (AREDS) report demonstrated that treatment with a vitamin/mineral formula consisting of vitamin C (500 mg), vitamin E (400 IU), beta-carotene (15 mg), zinc (80 mg), and cupric oxide (5 mg) reduces the risk of progression

to advanced AMD by approximately 25% over 5 years and reduces the risk of vision loss caused by advanced AMD by approximately 19% by 5 years. A second study (AREDS2) evaluated the role of increased intake of different carotenoids (lutein and zeaxanthin) as well as two specific omega-3 long-chain polyunsaturated fatty acids (docosahexaenoic acid [DHA] + eicosapentaenoic acid [EPA]). The addition of lutein + zeaxanthin, DHA + EPA, or both to the original AREDS formulation did not further reduce risk of progression to advanced AMD but was found to be equally effective.



**NOTE:** Beta-carotene (in the original AREDS formula) should be withheld in past or present smokers because of increased risk of lung cancer. The AREDS2 formulation (with lutein + zeaxanthin) is preferred as it does not contain beta-carotene.

In addition, recommend consumption of green leafy vegetables if approved by a primary care physician (intake of vitamin K decreases effectiveness of warfarin) and foods containing high levels of omega-3 fatty acids such as cold water fish and nuts.

1. Low-vision aids may benefit some patients with bilateral loss of macular function.
2. Refer to an internist for management of presumed risk factors: HTN, hypercholesterolemia, smoking cessation, etc.
3. Those at high risk for progressing to exudative AMD may benefit from home monitoring technology for earlier detection such as the PHP ForseeHome device. Early detection of CNV increases the likelihood of better visual acuity results after intravitreal anti-VEGF therapy is initiated.
4. Certain genetic mutations confer an increased risk for AMD (e.g., polymorphisms of complement factor H and ARMS2 genes). This may or may not influence response to treatment and so, at this time, genetic screening in AMD patients is not routinely performed.

### Follow Up

Every 6 to 12 months, watching for signs of the exudative form. Daily use of Amsler grid or PHP device with instructions to return promptly if a change is noted.

## REFERENCES

Age-Related Eye Disease Study Research Group. A randomized, placebo-controlled, clinical trial of high-dose supplementation with vitamins C and E, beta-carotene, and zinc for age-related macular degeneration and vision loss: AREDS report no. 8. *Arch Ophthalmol*. 2001;119:1417-1436.

The Age-Related Eye Disease Study 2 (AREDS2) Research Group. Lutein + zeaxanthin and omega-3 fatty

acids for age-related macular degeneration: The age-related eye disease study 2 (AREDS2) randomized clinical trial. *J Am Med Assoc*. 2013;309(19):2005-2015.

AREDS2-HOME Study Research Group; Chew EY, Clemons TE, et al. Randomized trial of a home monitoring system for early detection of choroidal neovascularization home monitoring of the Eye (HOME) study. AREDS2-HOME Study. *Ophthalmology*. 2014;121(2):535-544.

## 11.17 Neovascular or Exudative (Wet) Age-Related Macular Degeneration

### Symptoms

Variable onset of central visual loss, central or paracentral scotoma, metamorphopsia, photopias in the central visual field.

### Signs

(See Figures 11.17.1 and 11.17.2.)

**Critical.** Drusen and SRF, ME or RPE detachment associated with CNV.

**Other.** Subretinal or intraretinal blood. Retinal exudates, subretinal fibrosis (disciform scar). Retinal angiomatous proliferation (RAP) is an intraretinal variant of neovascular AMD and is characterized by focal telangiectatic retinal vessels with an adjacent superficial retinal hemorrhage and associated intraretinal edema and RPE detachment. Some neovascular AMD patients may present with VH.

### Risk Factors for Loss of Vision

Advanced age, hyperopia, blue eyes, family history, soft (large) drusen, focal subretinal pigment clumping, RPE detachments, systemic HTN, and smoking. Note that patients with wet AMD in one eye have a 10% to 12% risk per year of developing CNV in the fellow eye. The risk increases for eyes with multiple or confluent soft drusen with RPE clumping.

### Differential Diagnosis

- Ocular histoplasmosis syndrome: Small white-yellow chorioretinal scars and peripapillary atrophy. May also present with CNV. See 11.24, OCULAR HISTOPLASMOSIS.
- Angioid streaks: Bilateral subretinal red-brown or gray irregular bands often radiating from the optic disc. See 11.23, ANGIOID STREAKS.

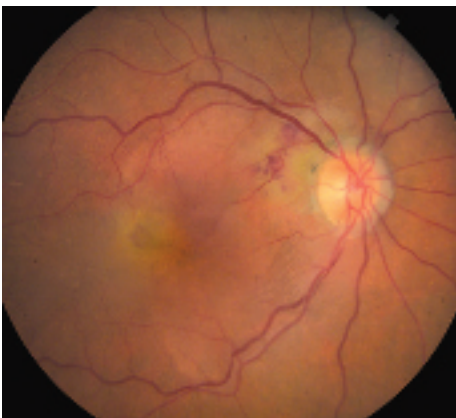


Figure 11.17.1 Exudative AMD.

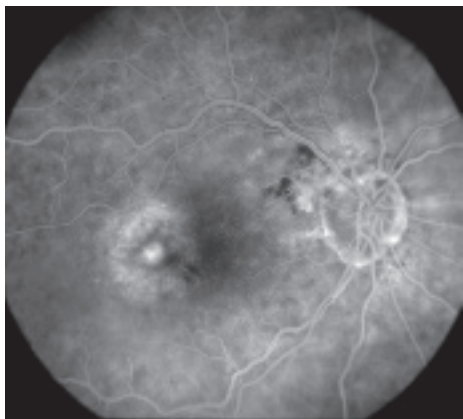


Figure 11.17.2 Intravenous fluorescein angiography of exudative AMD.



- High myopia: Significant myopic refractive error, lacquer cracks, tilted disc. See 11.22, HIGH MYOPIA.
  - Idiopathic polypoidal choroidal vasculopathy (IPCV): Multiple serosanguineous macular and RPE detachments. ICGA highlights characteristic choroidal polyp-like aneurysmal dilations most often located in the peripapillary region. This is considered a variant of neovascular AMD and is more common in those of Asian and African descent. See 11.18, IDIOPATHIC POLYPOIDAL CHOROIDAL VASCULOPATHY (POSTERIOR UVEAL BLEEDING SYNDROME).
  - Other CNV-predisposing conditions include drusen of the optic nerve, choroidal rupture, choroidal tumors, photocoagulation scars, inflammatory focal chorioretinal spots, and idiopathic causes.
3. OCT is helpful in determining retinal thickness, CNV thickness, location, and extent of ME, SRF, and RPE detachment. OCT is the primary modality for following response to treatment.
  4. ICGA may help delineate the borders of certain obscured occult CNV, particularly with subretinal blood or exudation. It also shows RAP and IPCV lesions better than IVFA.

### Treatment

- Ranibizumab: Anti-VEGF antibody fragment injected intravitreally that is FDA-approved for all CNV subtypes. In the original phase 3 efficacy trials (MARINA and ANCHOR), ranibizumab was given monthly to patients, with close to 40% of patients in both studies gaining three or more lines of visual acuity at 1 year. While the best visual results may occur with monthly dosing, PRN or treat-and-extend (TAE) individualized dosing regimens may yield similar visual results with less frequent injections.
- Aflibercept: Anti-VEGF fusion protein that binds all isoforms of VEGF-A and placental growth factor. FDA-approved as intravitreal injection for the treatment of neovascular AMD. Phase 3 VIEW studies showed similar efficacy at 1 year to monthly intravitreal ranibizumab with aflibercept dosed q8 weeks after a 12-week monthly induction phase.
- Bevacizumab: Full-length anti-VEGF antibody. Originally FDA-approved for systemic administration to treat colon cancer. Off-label use as intravitreal injection at a dose of 1.25 mg is effective in treating neovascular AMD. It is cost-effective and commonly used in clinical practice. The Comparison of Age-Related Macular Degeneration Treatments Trial (CATT) study demonstrated the non-inferiority of bevacizumab as compared to ranibizumab at 1 year.
- Brolicizumab: Single-chain humanized anti-VEGF antibody fragment that binds all isoforms of VEGF-A. FDA-approved as intravitreal injection for the treatment of neovascular AMD. Phase 3 studies when dosed at q8 or q12 week intervals based on disease activity demonstrated the noninferiority of brolicizumab as compared to aflibercept dosed at q8 week intervals at 1 year after a

### Types of Neovascular AMD Lesions

- Occult CNV (Type 1): Ill-defined, stippled, flat, or elevated subtle late leakage on IVFA and located in the sub-RPE location by OCT.
- Classic CNV (Type 2): Early-phase IVFA demonstrates a well-delineated area of lacy hyperfluorescence with prominent leakage in later phases and located in the sub-neurosensory retinal location by OCT.
- RAP (Type 3): Focal intraretinal hyperfluorescence on IVFA and ICGA. High-speed ICGA is particularly sensitive and may show characteristic “hair pin loop” with retinal feeder and draining vessels. OCTA shows this focal form of neovascularization to be intraretinal.

### Workup

1. Slit lamp biomicroscopy with a 60-, 90-diopter, or fundus contact lens to detect CNV and associated exudation. Must examine both eyes.
2. Perform IVFA or OCTA if CNV is suspected. IVFA is useful to confirm neovascular AMD size, type, and location. OCTA is useful as a noninvasive alternative to IVFA or when IVFA is inconclusive such as in pattern dystrophy or central CSCR. OCTA is also useful if there is an allergy to fluorescein dye or in pregnancy when it is best to avoid dye use.

12-week monthly induction phase (HAWK and HARRIER).

- PDT: FDA-approved intravenous infusion of photosensitizing dye (verteporfin) followed by nondestructive (cold) laser application to activate the dye within the CNV. PDT can be performed as often as every 3 months for 1 to 2 years. Small, classic subfoveal CNV responds best, but small occult or minimally classic subfoveal CNV may also respond. PDT decreases vision loss but does not improve vision as monotherapy. Now rarely used.
- Thermal laser photocoagulation: Results are best for extrafoveal CNV ( $\geq 200$   $\mu\text{m}$  from fovea) or peripapillary CNV. Laser photocoagulation treatment is complicated by high CNV recurrence rates. Uncommonly used.

### Follow Up

Depends on the treatment algorithm used, but typically monthly follow up until the CNV lesion is inactive with resolution of exudative signs based on examination and OCT. Patients receiving anti-VEGF therapy need indefinite

follow up, though the follow-up frequency depends on treatment response and treatment algorithm, for example, as needed (PRN) versus TAE. Patients receiving intravitreal injections should be given warning symptoms for endophthalmitis and RD.

### REFERENCES

- Rosenfeld PJ, Brown DM, Heier JS, et al. Ranibizumab for neovascular age-related macular degeneration. *N Engl J Med*. 2006;355:1419-1431.
- Lalwani GA, Rosenfeld PJ, Fung AE, et al. A variable-dosing regimen with intravitreal ranibizumab for neovascular age-related macular degeneration: year 2 of the PrONTO Study. *Am J Ophthalmol*. 2009;148(1):43-58.
- The CATT Research Group. Ranibizumab and bevacizumab for neovascular age-related macular degeneration. *N Engl J Med*. 2011;364:1897-1908.
- Heier JS, Brown DM, Chong V. Intravitreal aflibercept (VEGF trap-eye) in wet age-related macular degeneration. *Ophthalmology*. 2012;119:2537-2548.
- Dugel PU, Koh A, Ogura Y, et al. HAWK and HARRIER: phase 3, multicenter, randomized, double-masked trials of brodalumab for neovascular age-related macular degeneration. *Ophthalmology*. 2020;127(1):72-84.

## 11.18 Idiopathic Polypoidal Choroidal Vasculopathy

### Symptoms

Decreased central vision; may be sudden or gradual.

### Signs

**Critical.** Subretinal red-orange, polyp-like lesions of the choroidal vasculature. Can be macular (more symptomatic) or peripapillary (see Figure 11.18.1).

**Other.** Bilateral subretinal and/or sub-RPE blood, VH, circinate subretinal exudates, subretinal fibrosis (disciform scar), SRF, atypical CNV, and multiple serous PEDs.

### Risk Factors

More common in females, individuals of African or Asian descent, and in patients with HTN. Can occur at a younger age compared to neovascular AMD, but usually without significant drusen or geographic atrophy.

### Differential Diagnosis

- See 11.17, NEOVASCULAR OR EXUDATIVE (WET) AGE-RELATED MACULAR DEGENERATION.

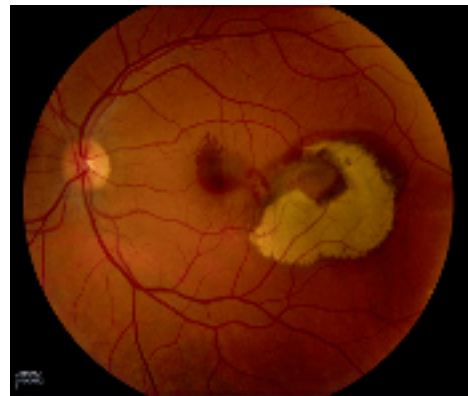

Figure 11.18.1 Polypoidal choroidal vasculopathy OS.

- See 11.19, RETINAL ARTERIAL MACROANEURYSM.
- Peripheral exudative hemorrhagic chorioretinopathy (PEHCR [peripheral CNV]): Occurs in the peripheral retina and presents with subretinal fluid, subretinal blood, exudation, RPE detachment, and/or subretinal fibrosis.

### Workup

1. Slit lamp biomicroscopy with a 60-, 90-diopter, or fundus contact lens to detect signs of exudation.
2. ICGA is the gold standard for diagnosis. ICGA is used to confirm the presence of a branching network of vessels arising from the inner choroidal circulation with terminal aneurysmal dilations (popcorn lesions). Unlike occult CNV, the IPCV lesions do not stain late unless active leakage is present.
3. IVFA is performed to evaluate for other causes of CNV.
4. OCT is used to assess for ME, SRF, and PEDs and can detect polyps in some eyes.

### Treatment

Asymptomatic lesions may be observed and may resolve spontaneously. IPCV with exudation and/or hemorrhagic complications has been treated

with anti-VEGF monotherapy, PDT, or a combination. The EVEREST-II and PLANET studies demonstrated level I evidence that anti-VEGF monotherapy as well as combination therapy give excellent functional visual outcomes in patients presenting with symptomatic IPCV. Thermal laser photocoagulation, feeder vessel treatment, and pneumatic displacement of large submacular hemorrhage have also been used with varying success.

### Follow Up

The prognosis of IPCV is generally better than for neovascular AMD. Symptomatic or macular IPCV is followed every 1 to 2 months with periodic OCT, IVFA, and ICGA as needed for disease progression. Consider treatment, or retreatment, if symptomatic, persistent, or new leakage occurs.

### REFERENCES

- Cheung CMG, Lai TYY, Ruamviboonsuk P, et al. Polypoidal choroidal vasculopathy: definition, pathogenesis, diagnosis, and management. *Ophthalmology*. 2018;125(5):708-724.
- Koh A, Lai TYY, Takahashi K, et al. Efficacy and safety of ranibizumab with or without verteporfin photodynamic therapy for polypoidal choroidal vasculopathy: a randomized clinical trial. *JAMA Ophthalmol*. 2017;135:1206-1213.

## 11.19 Retinal Arterial Macroaneurysm

### Symptoms

Decreased vision; history of systemic HTN. Usually unilateral, but 10% bilateral.

### Signs

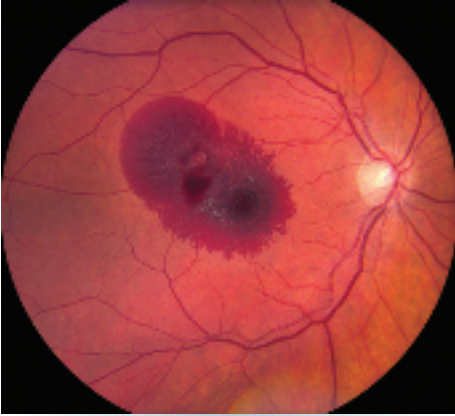(See Figures 11.19.1 and 11.19.2.)

**Critical.** Acute hemorrhages in multiple layers of the retina (subretinal, intraretinal, preretinal) possibly with VH; often with a white or yellow spot in the middle of the retinal arterial macroaneurysm (RAM). Chronic leakage may cause a ring of hard exudates and retinal edema around the aneurysm resulting in decreased vision if the macula is involved.

**Other.** ME, arteriolar emboli, capillary telangiectasia, arterial or venous occlusions distal to macroaneurysm.

### Differential Diagnosis

- Coats disease: Unilateral retinal vascular telangiectasias. Extensive yellow intraretinal and subretinal exudates. Hemorrhages not typical. See 8.1, LEUKOCORIA.
- Idiopathic retinal vasculitis, aneurysms, and neuroretinitis: A syndrome characterized by retinal vasculitis, multiple arterial macroaneurysms, neuroretinitis, and peripheral capillary nonperfusion.
- Diabetic retinopathy: Hemorrhages are not subretinal. See 11.12, DIABETIC RETINOPATHY.
- Valsalva retinopathy: No associated hard exudates. See 11.21, VALSALVA RETINOPATHY.
- Retinal telangiectasias: Juxtafoveal or parafoveal retinal telangiectasias can cause hard exudates in a circinate pattern usually temporal to macula. Association with diabetes.



**Figure 11.19.1** Retinal artery macroaneurysm on presentation.

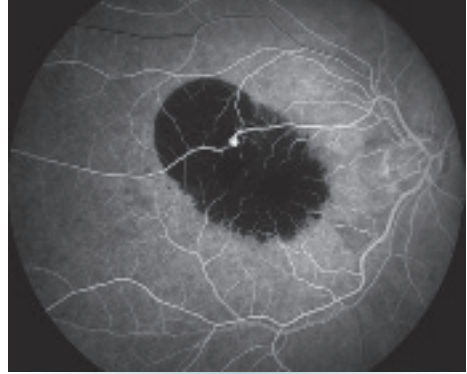- Others: Retinal capillary hemangioma (hemangioblastoma), retinal cavernous hemangioma, choroidal melanoma, hemorrhagic RPE detachment seen in AMD, IPCV, etc.

### Etiology

Acquired vascular dilation of retinal artery or arteriole usually at the site of arteriolar bifurcation or arteriovenous crossing. Usually related to systemic HTN and general atherosclerotic disease.

### Workup

1. History: Systemic disease, particularly HTN or diabetes?
2. Complete ocular examination with dilated retinal examination with a 60- or 90-diopter lens and indirect ophthalmoscopy. Look for concurrent retinal venous obstruction (present in one-third of cases) and signs of hypertensive retinopathy (visible in fellow eye as well).
3. Check blood pressure.



**Figure 11.19.2** Intravenous fluorescein angiography of a retinal artery macroaneurysm.

4. Consider checking lipid panel as well as fasting or random blood sugar and hemoglobin A1c.
5. IVFA may demonstrate early hyperfluorescence if there is no blockage from hemorrhage. Late frames may show leakage or staining of vessel wall.
6. OCT is helpful in demonstrating and following any ME.

### Treatment

Consider laser treatment if edema and/or exudate threatens central vision. Caution must be taken when treating arterioles that supply the central macula since distal thrombosis and obstruction with resultant ischemia can occur. Laser can also cause aneurysmal rupture resulting in retinal and vitreous hemorrhage. Anti-VEGF agents may be beneficial in patients with macroaneurysm-associated ME. Dense or nonclearing vitreous hemorrhage, sub-internal limiting membrane (ILM) hemorrhage, or thick submacular hemorrhage may benefit from vitrectomy.

### Follow Up

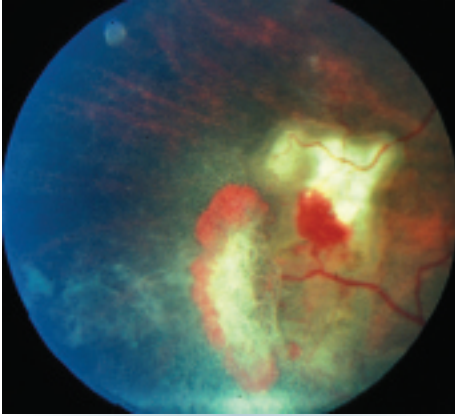
Frequency based on the amount and location of exudate and hemorrhage.

## 11.20 Sickle Cell Retinopathy (Including Sickle Cell Disease, Anemia, and Trait)

### Symptoms

Usually without ocular symptoms. Floaters, flashing lights, or loss of vision with advanced disease.

Systemically, patients often have painful crises with severe abdominal or musculoskeletal pain. Patients are typically of African or Mediterranean descent.



**Figure 11.20.1** Sickle cell retinopathy neovascular sea fan with associated vitreous hemorrhage.

## Signs

(See Figure 11.20.1.)

**Critical.** Peripheral retinal neovascularization in the shape of a fan (“sea fan sign”), sclerosed peripheral retinal vessels, or a dull gray peripheral fundus background color as a result of peripheral arteriolar occlusions and ischemia.

**Other.** Venous tortuosity, midperipheral fundus pigmented lesions with spiculated borders (black sunbursts), superficial intraretinal hemorrhages (salmon patch), refractile (iridescent) intraretinal deposits following hemorrhage resorption, angioid streaks, comma-shaped capillaries of the conjunctiva (especially along the inferior fornix). VH and traction bands, RD, CRAO, macular arteriolar occlusions, and enlargement of the foveal avascular zone occasionally develop.

## Staging

- Stage 1: Peripheral arteriolar occlusions.
- Stage 2: Peripheral arteriovenous anastomoses.
- Stage 3: Neovascular proliferation.
- Stage 4: VH.
- Stage 5: RD.

## Differential Diagnosis of Peripheral Retinal Neovascularization

- Sarcoidosis: Peripheral sea fan neovascularization often associated with uveitis. Increased frequency in young patients of African descent. See 12.6, SARCOIDOSIS.

- Diabetic retinopathy: Posterior pathology more prominent. Associated dot-blot hemorrhages. See 11.12, DIABETIC RETINOPATHY.
- Embolic (e.g., talc) retinopathy: History of intravenous drug abuse. May see refractile talc particles in macular arterioles. See 11.33, CRYSTALLINE RETINOPATHY.
- Eales disease: Peripheral retinal vascular occlusion of unknown etiology; diagnosis of exclusion.
- Others: Retinopathy of prematurity, FEVR, chronic myelogenous leukemia, radiation retinopathy, pars planitis, carotid–cavernous fistula, OIS, collagen vascular disease, hypercoagulable state. See specific sections.

## Workup

1. Medical history and family history: Sickle cell disease, diabetes, or known medical problems? Intravenous drug abuse?
2. Dilated fundus examination using indirect ophthalmoscopy.
3. Sickledex, sickle cell preparation, and hemoglobin electrophoresis.

**NOTE:** Patients with sickle cell trait (i.e., HbSC), as well as hemoglobin C disease, may have a negative Sickledex preparation. Retinopathy is most common with HbSC (most severe) and HbS-Thal and less common with HbSS (sickle cell disease).

1. Consider IVFA (particularly widefield) to aid in diagnostic and therapeutic considerations.

## Treatment

There are no well-established indications or guidelines for treatment. Isolated retinal neovascularization itself does not require treatment, as there may be a high probability of autoinfarction. Neovascularization with associated VH should receive PRP to the avascular area (anterior to the neovascularization). RD and VH may be best treated with vitrectomy. Anti-VEGF agents may be beneficial, but caution should be used in cases with significant traction.

## Follow Up

1. No retinopathy: Annual dilated fundus examinations.
2. Retinopathy present: Repeat dilated fundus examination every 3 to 6 months, depending on severity.

## 11.21 Valsalva Retinopathy

### Symptoms

Decreased vision or asymptomatic. History of Valsalva maneuver (forceful exhalation against a closed glottis), which may occur during heavy lifting, coughing, vomiting, or straining during bowel movement. Sometimes, no history of Valsalva can be elicited.

### Signs

(See Figure 11.21.1.)

**Critical.** Single or multiple hemorrhages under the ILM in the area of the macula. Can be unilateral or bilateral. Blood may turn yellow after a few days.

**Other.** Vitreous, intraretinal, subretinal, and subconjunctival hemorrhage can occur.

### Differential Diagnosis

- PVD: Can cause VH acutely as well as peripheral retinal and disc margin hemorrhages. However, sub-ILM hemorrhage is rare. See 11.1, POSTERIOR VITREOUS DETACHMENT.
- RAM: Hemorrhages in multiple layers of the retina and vitreous. Can also have a circinate ring of hard exudates around a macroaneurysm. See 11.19, RETINAL ARTERIAL MACROANEURYSM.
- Diabetic retinopathy: Microaneurysms, dot-blot hemorrhages, and hard exudates bilaterally. No isolated sub-ILM hemorrhage.

Can also cause VH. See 11.12, DIABETIC RETINOPATHY.

- CRVO or BRVO: Unilateral, multiple intraretinal hemorrhages, venous dilation, and tortuosity. See 11.8, CENTRAL RETINAL VEIN OCCLUSION and 11.9, BRANCH RETINAL VEIN OCCLUSION.
- Anemia or leukemia: May have multiple, bilateral flame and dot-blot hemorrhages as well as CWSS. Can also present with sub-ILM hemorrhage.
- RT: Can be surrounded by hemorrhage obscuring the tear. Tears rarely occur in the macula.

### Etiology

Valsalva causes sudden increase in intraocular venous pressure leading to rupture of superficial capillaries in macula or elsewhere in the retina. May be associated with anticoagulant therapy.

### Workup

1. History: History of Valsalva including any recent heavy lifting, straining during bowel movement, coughing, sneezing, vomiting, etc.? The patient may not remember the incident.
2. Complete ocular examination, including dilated retinal examination with a slit lamp and a 60- or 90-diopter lens, and indirect ophthalmoscopy. Look for findings suggestive of a different etiology including microaneurysms, dot-blot hemorrhages, CWSS, RT, PVD.
3. If dense VH is present, perform a B-scan US to rule out RT or RD.
4. IVFA may be helpful to rule out other causes including RAM or diabetic retinopathy.

### Treatment

Prognosis is excellent. Most patients are observed, as sub-ILM hemorrhage usually resolves after a few days to weeks. Occasionally laser is used to permit the blood to drain into the vitreous cavity, thereby uncovering the macula. Vitrectomy rarely considered, typically only for nonclearing VH.

### Follow Up

May follow up every 2 weeks for the initial visits to monitor for resolution, then follow up routinely.

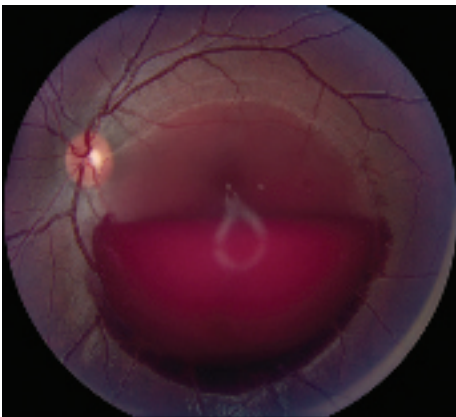

Figure 11.21.1 Valsalva retinopathy.

## 11.22 Pathologic/Degenerative Myopia

### Symptoms

Decreased vision. Usually asymptomatic until middle adulthood.

### Signs

(See Figure 11.22.1.)

**Critical.** Myopic crescent (a crescent-shaped area of white sclera or choroidal vessels adjacent to the disc, separated from the normal-appearing fundus by a hyperpigmented line); an oblique (tilted) insertion of the optic disc, with or without vertical elongation. Macular pigmentary abnormalities; hyperpigmented spots in the macula (Fuchs spots). Typically, a refractive correction of more than  $-6.00$  diopters, axial length  $\geq 26.5$  mm.

**Other.** Risk for CNV or RRD. Temporal optic disc pallor, posterior staphyloma, entrance of the retinal vessels into the nasal part of the optic cup. The retina and choroid may be seen to extend over the nasal border of the optic disc. Well-circumscribed areas of atrophy, spots of subretinal hemorrhage, choroidal sclerosis, yellow subretinal streaks (lacquer cracks), peripheral retinal thinning, and lattice degeneration may occur. Visual field defects may be present.

### Differential Diagnosis

- AMD: May develop CNV and a similar macular appearance, but typically drusen are

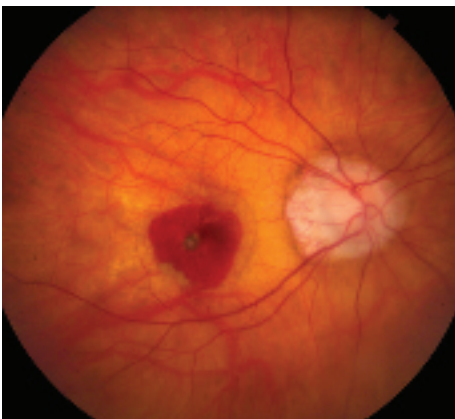

Figure 11.22.1 High myopia with macular hemorrhage.

present, and myopic disc features are absent. See 11.16, NONEXUDATIVE (DRY) AGE-RELATED MACULAR DEGENERATION and 11.17, NEOVASCULAR OR EXUDATIVE (WET) AGE-RELATED MACULAR DEGENERATION.

- Ocular histoplasmosis: Peripapillary atrophy with risk for CNV. A pigmented ring may separate the disc from the peripapillary atrophy, as opposed to a pigmented ring separating the atrophic area from the adjacent retina. Round choroidal scars (punched-out lesions) are scattered throughout the fundus. See 11.24, OCULAR HISTOPLASMOSIS.
- Tilted discs: Anomalous discs with a scleral crescent, most often inferonasally, an irregular vascular pattern as the vessels emerge from the disc (situs inversus), and an area of fundus ectasia in the direction of the tilt (inferonasally). Many patients have myopia and astigmatism but no chorioretinal degeneration or lacquer cracks. Visual field defects corresponding to the areas of fundus ectasia are often seen. Most cases are bilateral.
- Gyrate atrophy: Rare. Multiple, well-demarcated areas of chorioretinal atrophy that in childhood start in the midperiphery and then coalesce to involve a large portion of the fundus. Increased blood levels of ornithine. Patients are often highly myopic. See 11.28, RETINITIS PIGMENTOSA AND INHERITED CHORIORETINAL DYSTROPHIES.
- Toxoplasmosis: Well-circumscribed chorioretinal scar that does not typically develop CNV. Active disease shows retinitis and vitritis. See 12.5, TOXOPLASMOSIS.

### Workup

1. Manifest and/or cycloplegic refraction.
2. IOP measurement by applanation tonometry (Schiotz or Tono-pen tonometry may underestimate IOP in highly myopic eyes).
3. Dilated retinal examination with indirect ophthalmoscopy to search for retinal breaks or detachment. Scleral depression may be helpful but should be performed with care over a staphyloma.
4. Slit lamp biomicroscopy with a 60-, 90-diopter, or fundus contact lens to examine macula and search for CNV (gray or green

lesion beneath the retina, subretinal blood or exudate, or SRF).

5. IVFA for suspected CNV.
6. OCT can reveal CNV as well as macular detachment over a staphyloma. Additionally, OCT can be useful in identifying foveal schisis, a possible cause of vision loss in patients with high myopia.

### Treatment

1. Symptomatic retinal breaks are treated with laser photocoagulation, cryotherapy, or scleral buckling surgery. Treatment of asymptomatic retinal breaks may be considered when there is no surrounding pigmentation or demarcation line.
2. Anti-VEGF agents are used for CNV due to high myopia. Laser photocoagulation therapy may be considered for extrafoveal or

juxtafoveal CNV within several days of obtaining an IVFA, but is seldom performed. See 11.17, NEOVASCULAR OR EXUDATIVE (WET) AGE-RELATED MACULAR DEGENERATION.

3. For glaucoma suspects, a single visual field often cannot distinguish myopic visual field loss from early glaucoma. Progression of visual field loss in the absence of progressive myopia, however, suggests the presence of glaucoma and the need for therapy. See 9.1, PRIMARY OPEN ANGLE GLAUCOMA.
4. Recommend one-piece polycarbonate safety goggles for sports because of increased risk of choroidal rupture from minor trauma.

### Follow Up

In the absence of complications, reexamine every 6 to 12 months, watching for the related disorders discussed above.

## 11.23 Angioid Streaks

### Symptoms

Usually asymptomatic. Decreased vision may result from CNV.

### Signs

(See Figure 11.23.1.)

**Critical.** Bilateral reddish-brown or gray bands located deep to the retina, due to breaks within Bruch membrane, usually radiating in an irregular or spoke-like pattern from the optic disc. CNV may occur.

**Other.** Mottled fundus appearance with an orange hue (peau d'orange), most common in the temporal midperiphery. Subretinal hemorrhages after mild blunt trauma. Reticular pigmentary changes in the macula; small, white, pinpoint chorioretinal scars (histo-like spots) in the midperiphery; crystalline bodies within the macula. Drusen of the optic disc (especially with pseudoxanthoma elasticum [PXE]). Granular pattern of hyperfluorescent lines on IVFA. Widespread RPE damage is more evident on FAF compared to fundus ophthalmoscopy or IVFA.

### Differential Diagnosis

- Lacquer cracks of myopic chorioretinal degeneration: High myopia present. See 11.22, HIGH MYOPIA.
- Choroidal rupture: Subretinal streaks are usually concentric to the optic disc, yellow-white in color. See 3.18, TRAUMATIC CHOROIDAL RUPTURE.

### Etiology

Fifty percent of cases are associated with systemic diseases; the rest are idiopathic.

- PXE: Most common. Loose skin folds in the neck, axillae, and on flexor aspects of joints; cardiovascular complications; increased risk of gastrointestinal bleeds.

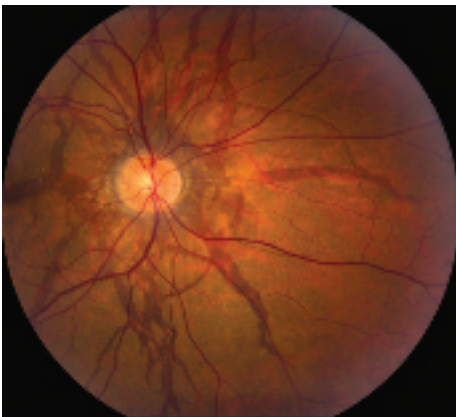

Figure 11.23.1 Angioid streaks.



- Ehlers–Danlos syndrome: Hyperelasticity of skin, loose joints.
- Paget disease of bone: Enlarged skull, bone pain, history of bone fractures, hearing loss, possible cardiovascular complications. May be asymptomatic but may develop visual loss due to optic nerve compression by enlarging bone. Increased serum alkaline phosphatase and urine calcium. Ten percent develop late angiod streaks.
- Sickle cell disease: May be asymptomatic or have decreased vision from fundus abnormalities. May have a history of recurrent infections and painless or painful crises. See 11.20, SICKLE CELL RETINOPATHY (INCLUDING SICKLE CELL DISEASE, ANEMIA, SICKLE AND TRAIT).
- Less common: Thalassemia, acromegaly, senile elastosis, lead poisoning, Marfan syndrome, hemolytic anemia, and others.

### Workup

1. History: Any known systemic disorders? Previous ocular trauma?
2. Complete ocular examination: Look carefully at the macula with a slit lamp using a 60-, 90-diopter, or fundus contact lens to detect CNV.
3. FAF if diagnosis uncertain or IVFA or OCTA if CNV suspected.

4. Physical examination: Look for clinical signs of etiologic diseases.
5. Serum alkaline phosphatase and urine calcium levels if Paget disease of bone is suspected.
6. Sickle cell preparation and hemoglobin electrophoresis in patients of African descent.
7. Skin or scar biopsy if PXE is suspected.
8. CBC if hematologic etiology suspected.

### Treatment

1. Anti-VEGF therapy is now used for angiod streak-associated CNV, as focal laser photocoagulation and PDT have discouraging outcomes. See 11.17, NEOVASCULAR OR EXUDATIVE (WET) AGE-RELATED MACULAR DEGENERATION.
2. Management of any underlying systemic disease by an internist.
3. Recommend wearing one-piece polycarbonate safety glasses for sports due to an increased risk of subretinal hemorrhage and choroidal rupture from minor trauma.

### Follow Up

1. Fundus examination every 6 months, monitoring for CNV.
2. Instruct patient to check Amsler grid daily and return immediately if changes are noted. See Appendix 4, AMSLER GRID.

## 11.24 Ocular Histoplasmosis

### Symptoms

Most often asymptomatic; can present with decreased or distorted vision, especially when CNV develops. Patients often have lived in or visited the Ohio–Mississippi River Valley or areas where histoplasmosis is endemic. Usually in the 20- to 50-year age range.

### Signs

(See Figure 11.24.1.)

**Critical.** Classic triad. Need two of the three to make the diagnosis:

1. Yellow-white, punched-out round spots, chorioretinal scars, usually <1 mm in diameter in any fundus location (histo-spots). Pigment clumps in or at the margin of the spots may be seen.

2. A macular CNV appearing as a gray-green patch beneath the retina, associated with retinal edema, SRF, subretinal blood or exudate, or a pigment ring evolving into a disciform scar.
3. Peripapillary atrophy or scarring, sometimes with nodules or hemorrhage. There may be a rim of pigment separating the disc from the area of atrophy or scarring.

**Other.** Curvilinear rows of small histo-spots in the peripheral fundus. No vitreous or aqueous cells.

### Differential Diagnosis

- Multifocal choroiditis with panuveitis: Similar clinical findings, except anterior or vitreous inflammatory cells or both, are also present. See 12.3, POSTERIOR UVEITIS.

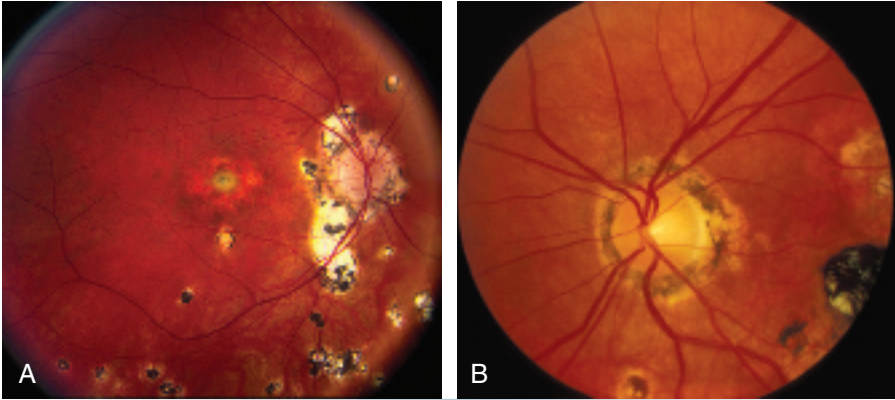


Figure 11.24.1 A and B: Ocular histoplasmosis.

- High myopia: May have atrophic spots in the posterior pole and a myopic crescent on the temporal side of the disc with a rim of pigment on the outer (not inner) edge, separating the crescent from the retina. Atrophic spots are whiter than histo-spots. See 11.22, HIGH MYOPIA.
- AMD: Macular changes may appear similar, but typically there are macular drusen and patients are  $\geq 50$  years of age. RPE more diffusely abnormal. There are no atrophic round spots similar to histoplasmosis and no scarring or atrophy around the disc. See 11.16, NONEXUDATIVE (DRY) AGE-RELATED MACULAR DEGENERATION and 11.17, NEOVASCULAR OR EXUDATIVE (WET) AGE-RELATED MACULAR DEGENERATION.
- Old toxoplasmosis: Pigmented chorioretinal lesion with fibrosis and overlying vitreous condensations. See 12.5, TOXOPLASMOSIS.
- Angioid streaks: Histo-like spots in the mid-periphery and macular degeneration may occur. Jagged red, brown, or gray lines deep to the retinal vessels and radiating from the optic disc. See 11.23, ANGIOID STREAKS.

## Etiology

Fungal infection caused by *Histoplasma capsulatum*. Once acquired by inhalation, the organisms can pass to the choroid through the bloodstream. Importantly, ocular histoplasmosis is *not* thought to represent active infection and antifungal therapy is not indicated.

## Workup

1. History: Time spent in the Ohio–Mississippi River Valley or endemic area? Prior exposure to fowl?
2. Amsler grid test (see Appendix 4, AMSLER GRID) to evaluate the central visual field of each eye.
3. Slit lamp examination: Anterior chamber or vitreous cells and flare should not be present.
4. Dilated fundus examination: Concentrate on the macular area with a slit lamp and 60-, 90-diopter, or fundus contact lens. Look for signs of CNV and vitreous cells.
5. IVFA and OCT to help detect CNV and monitor response to treatment.

## Treatment

1. Antifungal treatment is not helpful.
2. Intravitreal anti-VEGF therapy for CNV is the mainstay of treatment. PDT for subfoveal CNV and focal laser photocoagulation for extrafoveal CNV may rarely be used as well.

## Follow Up

1. Instruct all patients to use an Amsler grid daily and to return immediately if any sudden visual change is noted.
2. Patients treated with anti-VEGF injections are seen every 4 to 6 weeks, depending on clinical response to therapy. Generally, a more complete treatment response is achieved with

fewer injections than in AMD. Patients are often able to stop injections rather than undergoing lifelong treatment. Patients treated with PDT or focal laser are typically seen at 2 to 3 weeks, 4 to 6 weeks, 3 months, and 6 months after treatment, and then every 6 months thereafter.

3. A careful macular examination and OCT is performed at each visit. IVFA may be repeated whenever renewed neovascular activity is suspected.
4. Patients without CNV are seen every 6 months when macular changes are present in one or both eyes and yearly when no macular disease is present in either eye.

## 11.25 Vitreomacular Adhesion/Vitreomacular Traction/Macular Hole

### Symptoms

Variable decreased vision (typically around 20/200 level for a full-thickness hole, better for a partial-thickness hole), metamorphopsia, or central scotoma. Three times more likely in women; usually occurs in sixth to eighth decade. 10% bilateral.

### Signs

(See Figures 11.25.1 and 11.25.2.)

**Critical.** A full-thickness macular hole appears as a round, red spot in the center of the macula, usually from one-third to two-thirds of a disc diameter in size; may be surrounded by a gray halo/cuff of SRF. Vitreomacular traction (VMT) demonstrates loss of the normal foveolar depression and often a yellow spot or ring in the center of the macula.

**Other.** Small, yellow precipitates deep to the retina in the hole or surrounding retina; retinal cysts at the margin of the hole or a small operculum above the hole, anterior to the retina (Gass stage 3 or 4); or both.

### Gass Staging of Macular Hole

- Stage 1: An impending hole, yellow spot, or ring in fovea.
- Stage 2: Small full-thickness hole.
- Stage 3: Full-thickness hole with cuff of SRF, no PVD.
- Stage 4: Full-thickness hole with cuff of SRF, with complete PVD.

**NOTE:** A new classification system using OCT has been developed. It is based on size of the full-thickness hole, presence of VMT, and underlying etiology (e.g., primary VMT versus secondary trauma).

11

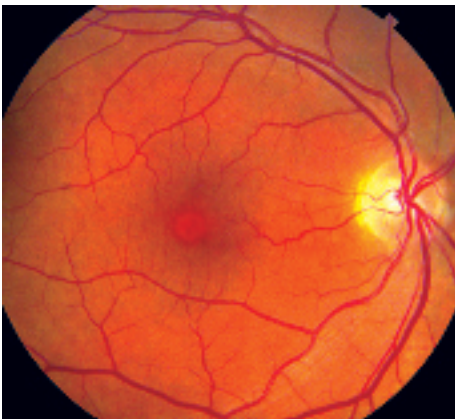


Figure 11.25.1 Macular hole.

### Differential Diagnosis

May be difficult to distinguish a macular hole from a pseudohole (no loss of foveal tissue) or a lamellar macular hole (partial-thickness).

- Macular pucker with a pseudohole: An ERM (surface-wrinkling) on the surface of the retina may simulate a macular hole. See 11.26, EPIRETINAL MEMBRANE (MACULAR PUCKER, SURFACE-WRINKLING RETINOPATHY, CELLOPHANE MACULOPATHY). Look for a sheen from ILM changes or ERM.
- Lamellar hole: Not as red as a full-thickness hole, and a surrounding gray halo is usually not present.

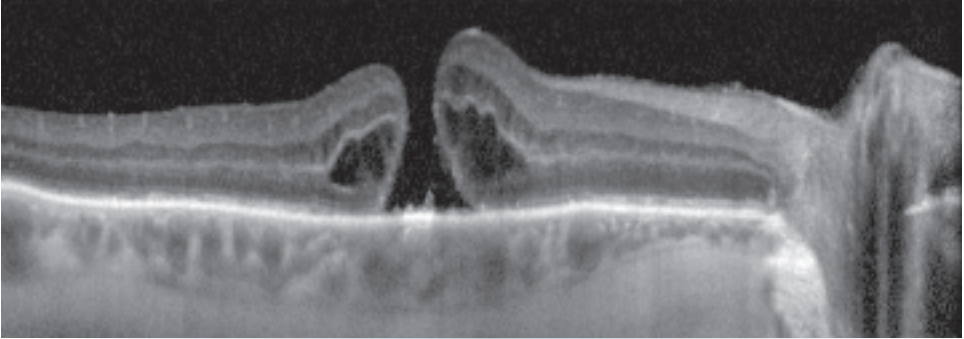


Figure 11.25.2 Optical coherence tomography of macular hole.

- Intraretinal cysts (e.g., chronic CME with prominent central cyst).
- Solar retinopathy: Small, round, red or yellow lesion at the center of the fovea, with surrounding fine gray pigment in a sun gazer or eclipse watcher. See 11.35, SOLAR RETINOPATHY.

### Etiology

May be caused by vitreous or ERM traction on the macula, trauma, or CME. In early stages of vitreomacular adhesion (VMA)/VMT, the vitreous cortex is attached to the fovea but detached from the perifoveal region, exerting anteroposterior traction on the fovea. Increased tractional forces can allow for eventual progression to full-thickness macular hole.

### Workup

1. History: Previous trauma? Previous eye surgery? Sun gazer?
2. Complete ocular examination, including a macular examination with a slit lamp and 60-, 90-diopter, or fundus contact lens. If a PVD is present, careful examination of the peripheral fundus to rule out peripheral breaks is important.
3. A true macular hole can be differentiated from a pseudo- or lamellar hole by directing a thin, vertical slit beam across the area in question using a 60- or 90-diopter lens with the slit lamp biomicroscope. The patient with a true hole will report a break in the line (Watzke–Allen test). A pseudohole or lamellar hole may cause distortion of the line, but it should not be broken.
4. IVFA may be helpful in identifying exudative retinal vascular disease (i.e., diabetic retinopathy, vein occlusion, pseudophakic CME) in cases which also have VMA/VMT.
5. OCT is critical for evaluating the vitreoretinal interface and determining the degree of traction from vitreous or ERMs. It is also useful in staging macular holes, differentiating from pseudo- or lamellar holes, and evaluating for progression (see Figure 11.25.3).

### Treatment

1. Stage 1 macular holes can be observed, as 50% resolve spontaneously.
2. Ocriplasmin is a recombinant protease with activity against components of the vitreoretinal interface (fibronectin and laminin). It is FDA-approved for the treatment of symptomatic VMA, VMT, and macular hole. It does not consistently work and rare, but important side effects such as ERG changes, lens subluxation, and dyschromatopsias have limited acceptance of this drug.
3. For symptomatic macular holes, pars plana vitrectomy with ILM peel and gas tamponade remains the gold standard for treatment. It is preferable to operate within the first 6 months of onset for highest chance of visual recovery. Serious complications are rare, but cataract progression in phakic patients is almost universal.

### Follow Up

1. Follow-up intervals vary depending on symptoms, examination, and surgical management.
2. Patients with high myopia are usually seen at least twice a year.

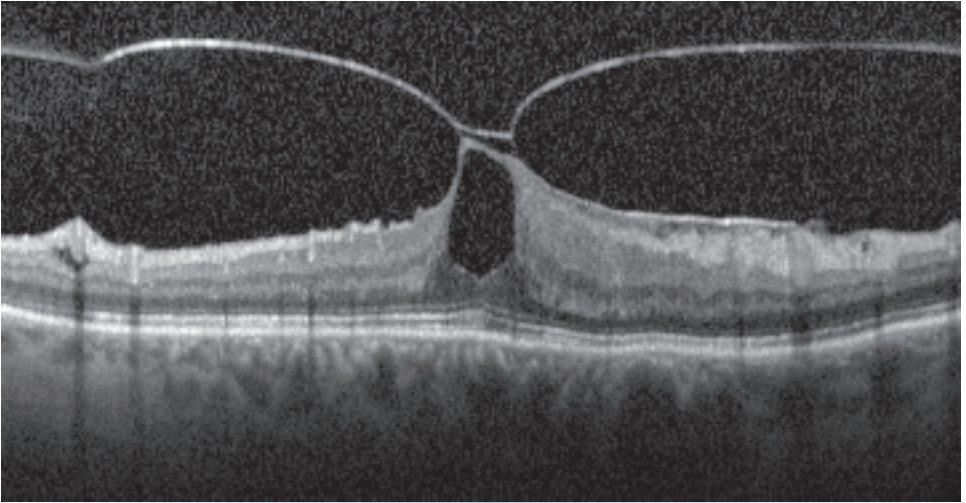


Figure 11.25.3 Optical coherence tomography of vitreomacular traction.

- All patients are seen promptly if RD symptoms develop.
- Because there is a small risk that the condition may develop in the contralateral eye, patients are given an Amsler grid for periodic home monitoring.

#### REFERENCE

Duker JS, Kaiser PK, Binder S, et al. The International Vitreomacular Traction Study Group classification of vitreomacular adhesion, traction, and macular hole. *Ophthalmology*. 2013;120(12):2611-2619.

## 11.26 Epiretinal Membrane (Macular Pucker, Surface-Wrinkling Retinopathy, Cellophane Maculopathy)

### Symptoms

Most are asymptomatic; can have decreased or distorted vision or both. Incidence increases with age. Twenty percent bilateral, though often asymmetric.

### Signs

(See Figure 11.26.1.)

**Critical.** Spectrum ranges from a fine, glistening membrane (cellophane maculopathy) to a thick, gray-white membrane (macular pucker) present on the surface of the retina in the macular area.

**Other.** Retinal folds radiating out from the membrane; displacement, straightening, or tortuosity of the macular retinal vessels; ME or macular detachment. A ring-shaped condensation of the ERM around the fovea may simulate a macular hole (pseudohole).

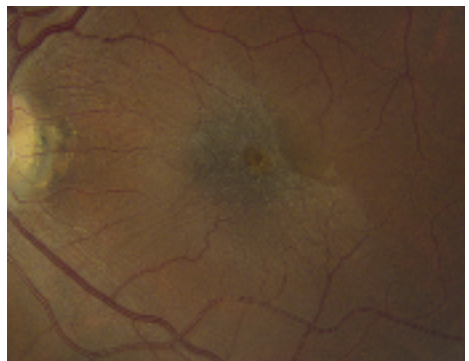


Figure 11.26.1 Epiretinal membrane with pseudohole.

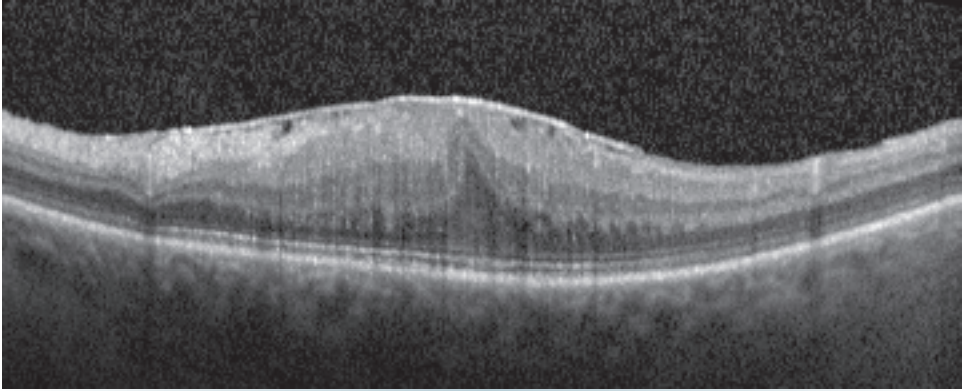


Figure 11.26.2 Optical coherence tomography of epiretinal membrane.

### Differential Diagnosis

- Diabetic retinopathy: May produce preretinal fibrovascular tissue, which may displace retinal vessels or detach the macula. ME may be present. See 11.12, DIABETIC RETINOPATHY.
- CME. See 11.14, CYSTOID MACULAR EDEMA.

### Etiology

- PVD. See 11.1, POSTERIOR VITREOUS DETACHMENT.
- Retinal break, RRD. A higher risk of ERM for PVD patients who also have a tear or RRD versus PVD alone. See 11.2, RETINAL BREAK and 11.3, RETINAL DETACHMENT.
- Idiopathic. ERM can occur without obvious cause and has been seen in very young children.
- After retinal cryotherapy or photocoagulation.
- After intraocular surgery, trauma, or vitreous hemorrhage.
- Uveitis. See Chapter 12, UVEITIS.
- Other retinal vascular disease (diabetic retinopathy, vein occlusion, etc.).

### Workup

1. History: Previous eye surgery or eye disease? Diabetes?
2. Complete ocular examination, particularly a thorough dilated fundus evaluation and careful macula evaluation with a slit lamp and a 60- or 90-diopter, Hruby, or fundus contact lens. A careful peripheral examination should be performed to rule out a retinal break.
3. OCT is helpful in evaluating ERMs (see Figure 11.26.2).

### Treatment

1. Treat the underlying disorder.
2. Examine the periphery to rule out a retinal break.
3. Surgical peeling of the membrane can be considered when it significantly reduces the vision.

### Follow Up

This is not an emergent condition, and treatment may be instituted at any time. Often does not progress over time. A small percentage of ERMs recur after surgical removal.

## 11.27 Choroidal Effusion/Detachment



### Symptoms

Decreased vision or asymptomatic in a serous choroidal detachment. Decreased vision may occur if the choroidal detachments extend posteriorly with a shadow or involve the macula. Moderate-to-severe pain and red eye may also occur with a hemorrhagic choroidal detachment.

### Signs

(See Figure 11.27.1.)

**Critical.** Smooth, bullous, orange-brown elevation of the retina and choroid that usually extends 360 degrees around the periphery in a lobular configuration. The ora serrata can be seen without scleral depression.

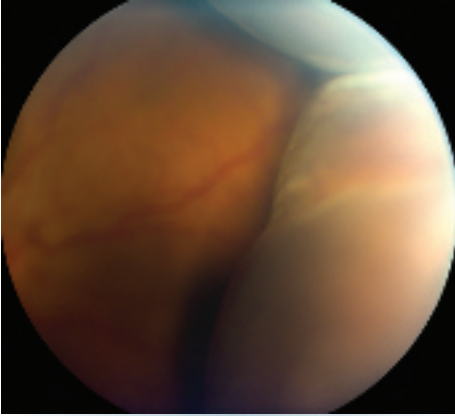


Figure 11.27.1 Choroidal detachment.

**Other.** *Serous choroidal detachment:* Low IOP (often <6 mm Hg), shallow anterior chamber with mild cell and flare, positive transillumination.

*Hemorrhagic choroidal detachment:* High IOP (if detachment is large), shallow anterior chamber with mild cell and flare, no transillumination.

### Differential Diagnosis

- Melanoma of the ciliary body: Not typically multilobular or symmetric in each quadrant of the globe. Pigmented melanomas do not transilluminate. B-scan US usually helps to differentiate between the two. See 11.36, CHOROIDAL NEVUS AND MALIGNANT MELANOMA OF THE CHOROID.
- RRD: Appears white and undulates with eye movements. A break is usually seen in the retina, and pigment cells are often present in the vitreous. Serous choroidal detachment can occur as the result of chronic RRD. See 11.3, RETINAL DETACHMENT.

### Etiology

#### Serous

- Intraoperative or postoperative: Wound leak, perforation of the sclera from a superior rectus bridle suture, iritis, cyclodialysis cleft, leakage or excess filtration from a filtering bleb, after RD repair by scleral buckling or vitrectomy, or after laser photocoagulation or cryotherapy.
- Traumatic: Often associated with a ruptured globe.
- Uveitis: posterior uveitis or scleritis.

- Other: Nanophthalmos, uveal effusion syndrome, carotid–cavernous fistula, primary or metastatic tumor, etc. See specific sections.

### Hemorrhagic

- Intraoperative or postoperative: From anterior displacement of the ocular contents and rupture of the short posterior ciliary arteries.
- Spontaneous (e.g., after perforation of a corneal ulcer). May have no inciting event, especially if on anticoagulants.

### Workup

1. History: Recent ocular surgery or trauma? Known eye or medical problem?
2. Slit lamp examination: Check for presence of a filtering bleb and perform Seidel test to rule out a wound leak. See Appendix 5, SEIDEL TEST TO DETECT A WOUND LEAK.
3. Gonioscopy of the anterior chamber angle: Look for a cyclodialysis cleft.
4. Dilated retinal examination: Determine whether there is SRF, indicating a concomitant RD, and whether an underlying choroidal disease or tumor is present. Examination of the contralateral eye may be helpful in diagnosis.
5. In cases suggestive of melanoma, B-scan US and transillumination of the globe are helpful in making a diagnosis. B-scan US is also useful in distinguishing between serous and hemorrhagic choroidal detachment and in determining if hemorrhage is mobile or coagulated.

### Treatment

#### General Treatment

1. Cycloplegic (e.g., atropine 1% t.i.d.).
2. Topical steroid (e.g., prednisolone acetate 1% four to six times per day).
3. Consider oral steroids.
4. Surgical drainage of the suprachoroidal fluid may be indicated for a flat or progressively shallow anterior chamber, particularly in the presence of inflammation (because of the risk of peripheral anterior synechiae), or corneal decompensation resulting from lens–cornea touch. “Kissing” choroidals (apposition of two lobules of detached choroid) can usually be tolerated as long as there is not intractable pain or IOP elevation.

**Specific Treatment: Repair the Underlying Problem**

## 1. Serous:

- Wound or filtering bleb leak: Patch for 24 hours, decrease steroids and add aqueous suppressants, suture the site, use cyanoacrylate glue, place a bandage contact lens on the eye, or a combination of these.
- Cyclodialysis cleft: Laser therapy, diathermy, cryotherapy, or suture the cleft to close it.
- Uveitis: Topical cycloplegic and steroid as discussed previously.

- Inflammatory disease: See the specific entity.
- RD: Surgical repair. Proliferative vitreoretinopathy after repair is common.

2. Hemorrhagic: Drainage of the choroidal detachment using intraocular infusion with or without vitrectomy is performed for severe cases. More successful if hemorrhage is liquefied, which occurs 7 to 10 days after the initial event. Otherwise use general treatment.

**Follow Up**

In accordance with the underlying problem.

## 11.28 Retinitis Pigmentosa and Inherited Chorioretinal Dystrophies

**RETINITIS PIGMENTOSA****Symptoms**

Decreased night vision (often night blindness) and loss of peripheral vision. Decrease in central vision can occur early or late in the disease process depending on whether rod or cone involvement is predominant. The same is true for color vision.

**Signs**

(See Figure 11.28.1.)

**Critical.** Classically, vitreous cells (most consistent sign), clumps of pigment dispersed throughout the peripheral retina in a perivascular pattern, often

assuming a “bone spicule” arrangement (though bone spicules may be absent), areas of RPE depigmentation or atrophy, arteriolar narrowing, and, later, waxy optic disc pallor. Progressive visual field loss, usually a ring scotoma, which progresses to a small central field. ERG usually moderately to markedly reduced.

**Other.** Focal or sectoral pigment clumping, CME, ERM, posterior subcapsular cataract.

**Inheritance Patterns**

- Autosomal recessive (most common): Diminished vision (severe) and night blindness occur early in life.
- Autosomal dominant (least severe): More gradual onset of RP, typically in adult life, variable penetrance, late onset of cataract. Visual loss less severe.
- X-linked recessive (rarest and most severe): Onset similar to autosomal recessive. Female carriers often have salt-and-pepper fundus. Visual loss is severe.
- Sporadic.

**Treatment**

Some evidence supports that diets high in vitamin A (15,000 IU/d) and lutein (12 mg/d) may help slow midperipheral visual field loss in nonsmokers with RP, but the literature remains inconclusive. If high-dose vitamin A therapy is initiated, monitor liver function tests and vitamin A levels. Both epiretinal and subretinal microchip implants have been used with some success to

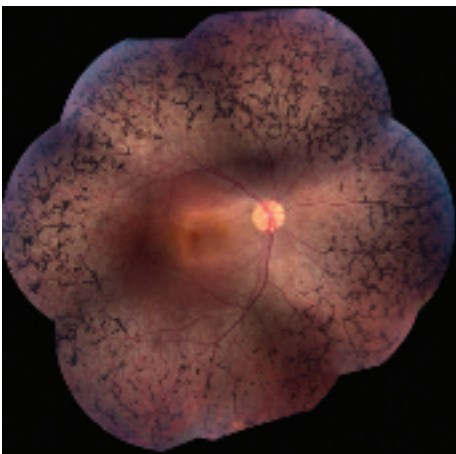
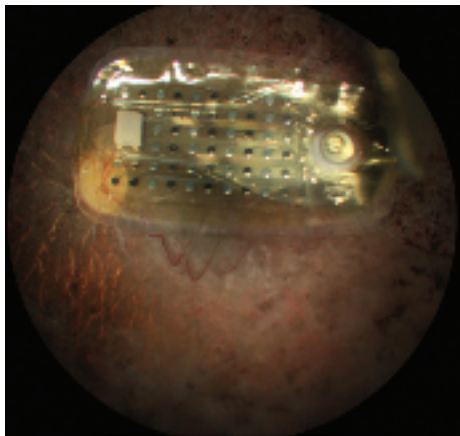


Figure 11.28.1 Retinitis pigmentosa.





**Figure 11.28.2** Epiretinal microchip implant in patient with advanced retinal pigment epithelium.

improve vision in patients with very advanced RP (see **Figure 11.28.2**). Clinical trials are ongoing with a variety of designs to determine the safety and efficacy of retinal implant technology. In addition, research in gene therapy for specific types of RP is underway.

### SYSTEMIC DISEASES ASSOCIATED WITH HEREDITARY RETINAL DEGENERATION

#### Refsum Disease (Phytanoyl-CoA Hydroxylase Deficiency)

Autosomal recessive RP (often without bone spicules) with increased serum phytanic acid level. May have cerebellar ataxia, peripheral neuropathy, deafness, dry skin, anosmia, liver disease, and cardiac abnormalities. Treat with low-phytanic acid, low-phytol diet (minimize the amount of milk products, animal fats, and green leafy vegetables). Check serum phytanic acid levels every 6 months.

#### Hereditary Abetalipoproteinemia (Bassen–Kornzweig Syndrome)

Autosomal recessive RP (usually without bone spicules) with fat intolerance, diarrhea, crenated erythrocytes (acanthocytes), ataxia, progressive restriction of ocular motility, and other neurologic symptoms as a result of deficiency in lipoproteins and malabsorption of the fat-soluble vitamins (A, D, E, and K). Diagnosis based on serum apolipoprotein-B deficiency.

#### Treatment

1. Water-miscible vitamin A, 10,000 to 15,000 IU p.o. daily.
2. Vitamin E, 200 to 300 IU/kg p.o. daily.
3. Vitamin K, 5 mg p.o. weekly.
4. Restrict dietary fat to 15% of caloric intake.
5. Biannual serum levels of vitamins A and E; yearly ERG, and dark adaptometry.
6. Consider supplementing the patient's diet with zinc.

#### Leber Congenital Amaurosis

Group of autosomal recessive retinal dystrophies that represent the most common genetic cause of congenital blindness in children. Fundus appearance is variable but typically shows a pigmentary retinopathy. Moderate-to-severe vision loss identified at or within a few months of birth, infantile nystagmus, poor and/or paradoxical pupillary response, photophobia, oculodigital sign (eye poking), and markedly reduced or flat ERG. Associated with keratoconus. Voretigene neparvovec (Luxturna) is the first FDA-approved gene therapy for any inherited retinal degeneration. Treatment involves subretinal injection of an AAV2 viral vector carrying RPE65 DNA.

#### Usher Syndrome

Multiple subtypes exist, all autosomal recessive. Associated with congenital sensorineural hearing loss which is usually stable throughout adult life. Genes involved code a protein complex present in inner ear hair cells and retinal photoreceptor cells. Molecular testing for certain subtypes is available.

#### Bardet–Biedl Complex

Mainly autosomal recessive group of different diseases with similar findings including pigmentary retinopathy, hypogonadism, obesity, polydactyly, mental retardation, and others. Lawrence–Moon syndrome is a related but separate entity associated with spastic paraplegia, but without the polydactyly and obesity.

#### Kearns–Sayre Syndrome

Salt-and-pepper pigmentary degeneration of the retina with normal arterioles. Progressive limitation of ocular movement without diplopia, ptosis, short stature, and/or cardiac conduction defects.

Ocular signs usually appear before age 20 years. Mitochondrial inheritance. Refer the patient to a cardiologist. Patients may need a pacemaker. See 10.12, CHRONIC PROGRESSIVE EXTERNAL OPHTHALMOPLÉGIA.

### Other RP Syndromes

- **Spielmeier–Vogt–Batten–Mayou syndrome:** Associated with seizures, dementia, and ataxia.
- **Alström, Cockayne, and Alport syndromes:** Associated with hearing loss.
- **Zellweger syndrome:** Associated with hypotonia, hypertelorism, and hepatomegaly.
- **Others:** Incontinentia pigmenti, Jansky–Bielschowsky, etc.

### Differential Diagnosis

- **Phenothiazine toxicity**
  - **Thioridazine:** Pigment clumps between the posterior pole and the equator, areas of retinal depigmentation, retinal edema, visual field abnormalities (central scotoma and general constriction), depressed or extinguished ERG. Symptoms and signs may occur within weeks of starting phenothiazine therapy, particularly if very large doses ( $\geq 2,000$  mg/d) are taken. Usually, more than 800 mg/d chronically needed for toxicity. Discontinue if toxicity develops. Follow every 6 months.
  - **Chlorpromazine:** Abnormal pigmentation of the eyelids, cornea, conjunctiva (especially within the palpebral fissure), and anterior lens capsule; anterior and posterior subcapsular cataract; rarely, a pigmentary retinopathy with visual field and ERG changes similar to that described for thioridazine. Usually, 1,200 to 2,400 mg/d for longer than 12 months needed for toxicity. Discontinue if toxicity develops. Follow every 6 months.
- **Syphilis:** Positive bloodwork, asymmetric visual fields, abnormal fundus appearance, may have a history of recurrent uveitis. No family history of RP. The ERG is usually preserved to some degree.
- **Congenital rubella:** A salt-and-pepper fundus appearance may be accompanied by microphthalmos, cataract, deafness, a congenital heart abnormality, or another systemic abnormality. The ERG is usually normal.

- **Bietti crystalline dystrophy:** Autosomal recessive condition characterized by crystals of unknown composition in the peripheral corneal stroma and in the retina at different layers. Can cause choroidal atrophy, decreased night vision, decreased visual acuity, and a flat ERG.
- **After resolution of a serous RD:** The history is diagnostic (e.g., toxemia of pregnancy, Harada disease).
- **Pigmented paravenous retinochoroidal atrophy:** Paravenous localization of RPE degeneration and pigment deposition. No definite hereditary pattern. Variable visual fields and ERG (usually normal).
- **After severe blunt trauma:** Usually due to spontaneous resolution of RD.
- **After ophthalmic artery occlusion.**
- **Carriers of ocular albinism:** See 13.8, ALBINISM.



**NOTE:** The pigment abnormalities are at the level of the RPE with phenothiazine toxicity, syphilis, and congenital rubella. With resolved RD, the pigment is intraretinal.

### Workup

1. Medical and ocular history pertaining to the diseases discussed previously.
2. Drug history.
3. Family history with pedigree and genetic testing for diagnostic and counseling purposes (see above).
4. Ophthalmoscopic examination.
5. Formal visual field testing (e.g., Humphrey).
6. Dark-adaptation studies and ERG: May help distinguish stationary rod dysfunction (congenital stationary night blindness) from RP (a progressive disease).
7. Fundus photographs.
8. Consider syphilis testing (RPR or VDRL and FTA-ABS or treponemal-specific assay).
9. If the patient is male and inheritance pattern is unknown, examine his mother and perform an ERG on her. Women carriers of X-linked disease often have abnormal pigmentation in the midperiphery and abnormal results on dark-adapted ERGs.
10. If neurologic abnormalities such as ataxia, polyneuropathy, deafness, or anosmia are present, obtain a fasting (at least 14 hours) serum phytanic acid level to rule out Refsum disease.

- If hereditary abetalipoproteinemia is suspected, obtain serum cholesterol and triglyceride levels (levels are low), a serum protein and lipoprotein electrophoresis (lipoprotein deficiency is detected), and peripheral blood smears (acanthocytosis is seen).
- If Kearns–Sayre syndrome is suspected, the patient must be examined by a cardiologist with sequential EKGs; patients can die of complete heart block. All family members should be evaluated.

### Treatment

For syphilis, see 12.12, SYPHILIS. For vitamin A deficiency, see 13.7, VITAMIN A DEFICIENCY.

No definitive treatment for RP is currently known. See above, RETINITIS PIGMENTOSA.

Cataract surgery may improve central visual acuity. Topical or oral carbonic anhydrase inhibitors (e.g., acetazolamide 500 mg/d) may be effective for CME.

All patients benefit from genetic counseling and instruction on how to deal with their visual handicaps. Tinted lenses may provide comfort outdoors and may provide better contrast enhancement. In advanced cases, low-vision aids and vocational rehabilitation are helpful.

### HEREDITARY CHORIORETINAL DYSTROPHIES AND OTHER CAUSES OF NYCTALOPIA (NIGHT BLINDNESS)

- Gyrate atrophy: Nyctalopia and decreased peripheral vision usually presenting in the first decade of life, followed by progressive constriction of visual field. Scalloped RPE and choriocapillaris atrophy in the midperiphery during childhood that coalesces to involve the entire fundus, posterior subcapsular cataract, high myopia with astigmatism. Constriction of visual fields and abnormal to nonrecordable ERG. Plasma ornithine level is 10 to 20 times normal; lysine is decreased. Consider ERG and IVFA if the ornithine level is not markedly increased. Autosomal recessive.

### Treatment

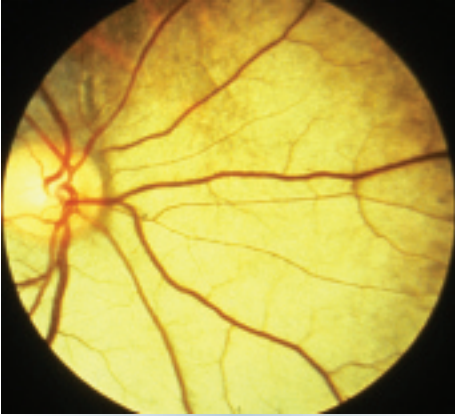
- Reduce dietary protein consumption and substitute artificially flavored solutions of essential amino acids without arginine (e.g., arginine-restricted diet). Monitor serum ammonia levels.

- Supplemental vitamin B6 (pyridoxine). The dose is not currently established; consider 20 mg/d p.o. initially and increase up to 500 mg/d p.o. if there is no response. Follow serum ornithine levels to determine the amount of supplemental vitamin B6 and the degree to which dietary protein needs to be restricted. Serum ornithine levels between 0.15 and 0.2 mmol/L are optimal.

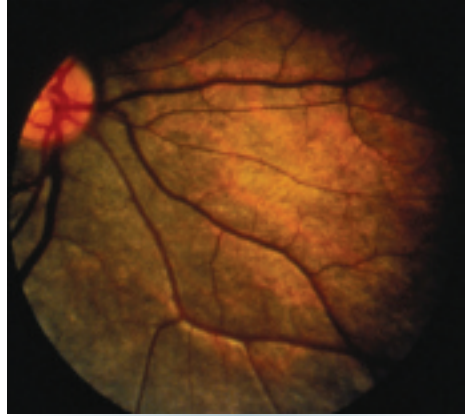


**NOTE:** Only a small percentage of patients are vitamin B6 responders.

- Choroideremia: Males present in the first to second decade of life with nyctalopia, followed by insidious loss of peripheral vision. Decreased central vision occurs late. In males, early findings include dispersed pigment granules in the periphery with focal areas of RPE atrophy. Late findings include total absence of RPE and choriocapillaris. No bone spicules. Retinal arteriolar narrowing and optic atrophy can occur late in the process. Constriction of visual fields, normal color vision, markedly reduced ERG. Female carriers have small, scattered, square intraretinal pigment granules overlying choroidal atrophy, most marked in the midperiphery. No effective treatment for this condition is currently available. Darkly tinted sunglasses may ameliorate symptoms. X-linked recessive. Consider genetic counseling.
- Vitamin A deficiency: Marked night blindness. Numerous small, yellow-white, well-demarcated spots deep in the retina seen peripherally. Dry eye and/or Bitôt spots (white keratinized lesions) on the conjunctiva. See 13.7, VITAMIN A DEFICIENCY.
- Zinc deficiency: May cause abnormal dark adaptation (zinc is needed for vitamin A metabolism).
- Congenital stationary night blindness: Night blindness from birth, normal visual fields; may have a normal or abnormal fundus, not progressive. Paradoxical pupillary response. One variant is Oguchi disease, characterized by the Mizuo phenomenon—the fundus has a tapetum appearance in the light-adapted state but appears normally colored when dark-adapted (may take up to 12 hours) (see **Figures 11.28.3** and **11.28.4**).
- Undercorrected myopia: The most common cause of poor night vision.



**Figure 11.28.3** Oguchi disease with fundus exhibiting tapetum appearance in a light-adapted state.



**Figure 11.28.4** Oguchi disease exhibiting Mizuo phenomenon, with a normally colored fundus in dark-adapted state.

## 11.29 Cone Dystrophies

### Symptoms

Slowly progressive visual loss, photophobia, and poor color vision, with onset during the first 3 decades of life. Vision is worse in bright than dim light.

### Signs

#### Critical

- Early: Essentially normal fundus examination, even with poor visual acuity. Abnormal cone function on ERG (e.g., a reduced single-flash photopic response and a reduced flicker response).
- Late: Bull's eye macular appearance or central geographic atrophy of the RPE and choriocapillaris.

**Other.** Nystagmus, temporal pallor of the optic disc, spotty pigment clumping in the macular area, tapetal-like retinal sheen. Rarely rod degeneration may ensue, leading to an RP-like picture (e.g., a cone-rod degeneration, which may have an autosomal dominant inheritance pattern).

### Inheritance

Usually sporadic. Hereditary forms are usually autosomal dominant or less often X-linked.

### Differential Diagnosis

- Stargardt disease: Especially in early stage when yellowish lesions are absent and ERG is usually normal. See 11.30, STARGARDT DISEASE (FUNDUS FLAVIMACULATUS).
- Chloroquine/hydroxychloroquine maculopathy: May produce a bull's eye macular appearance and poor color vision. History of medication use, no family history of cone degeneration, no nystagmus. See 11.32, CHLOROQUINE/HYDROXYCHLOROQUINE TOXICITY.
- Central areolar choroidal dystrophy: Geographic atrophy of the RPE with normal photopic ERG.
- AMD: Can have geographic atrophy of the RPE, but with normal color vision and photopic ERG. See 11.16, NONEXUDATIVE (DRY) AGE-RELATED MACULAR DEGENERATION and 11.17, NEOVASCULAR OR EXUDATIVE (WET) AGE-RELATED MACULAR DEGENERATION.
- Congenital color deficiency: Normal visual acuity, onset at birth, not progressive.
- RP: Night blindness and peripheral visual field loss. Often with peripheral retinal bone spicules. Can be distinguished by dark-adaptation testing and ERG. See 11.28, RETINITIS PIGMENTOSA AND INHERITED CHORIORETINAL DYSTROPHIES.

- Optic neuropathy or atrophy: Decreased acuity, impaired color vision, temporal or diffuse optic disc pallor, or both. See 10.17, ARTERITIC ISCHEMIC OPTIC NEUROPATHY (GIANT CELL ARTERITIS), 10.18, NONARTERITIC ISCHEMIC OPTIC NEUROPATHY, and 10.20, MISCELLANEOUS OPTIC NEUROPATHIES.
- Nonphysiologic visual loss: Normal results on ophthalmoscopic examination, IVFA, OCT, ERG, and electrooculogram (EOG). Patients can often be tricked into seeing better by special testing. See 10.25, NONPHYSIOLOGIC VISUAL LOSS.

### Workup

1. Family history.
2. Complete ophthalmic examination, including formal assessment for dyschromatopsia (e.g., Farnsworth–Munsell 100-hue test).
3. Formal visual field test.
4. Full-field ERG: abnormal photopic response with normal rod-isolated response.

5. OCT can show disruption of outer retinal layers but may be normal even in patients with electrophysical abnormalities.
6. FAF can be useful in the diagnosis (particularly sensitive to disturbances in the RPE), as well as for monitoring these diseases.

### Treatment

There is no proven cure for cone dystrophy. The following measures may be palliative:

1. Heavily tinted glasses or contact lenses may help maximize vision.
2. Miotic drops (e.g., pilocarpine 0.5% to 1% q.i.d.) are occasionally tried to improve vision and reduce photophobia.
3. Genetic counseling.
4. Low-vision aids as needed.

### Follow Up

Yearly.

## 11.30 Stargardt Disease (Fundus Flavimaculatus)

### Symptoms

Decreased vision in childhood or young adulthood. Early in the disease, the decrease in vision is often out of proportion to the clinical ophthalmoscopic appearance; therefore, care must be taken not to label the child a malingerer.

### Signs

(See Figures 11.30.1 to 11.30.3.)

**Critical.** Any of the following may be present.

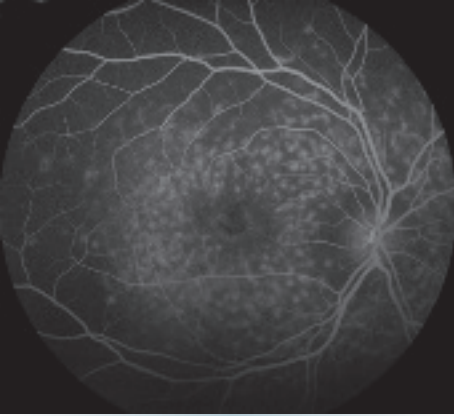
- A relatively normal-appearing fundus except for slight granularity in the foveola.
- Yellow or yellow-white, fleck-like deposits at the level of the RPE, often in a pisciform (fish-tail) configuration.
- Atrophic macular degeneration: May have a bull's eye appearance as a result of atrophy of the RPE around a normal central core of RPE, a "beaten-metal" appearance, pigment clumping, or marked geographic atrophy.

**NOTE:** In early stages, vision declines before visible macular changes develop.

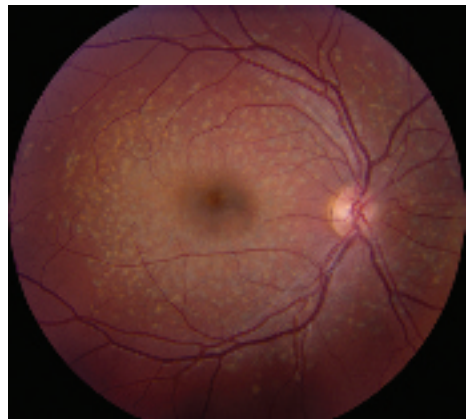

Figure 11.30.1 Stargardt disease.

**Other.** Atrophy of the RPE just outside of the macula or in the midperipheral fundus, normal peripheral visual fields in most cases, and rarely an accompanying cone or rod dystrophy. The ERG is typically normal in the early stages but may become abnormal late in the disease. The EOG can be subnormal.



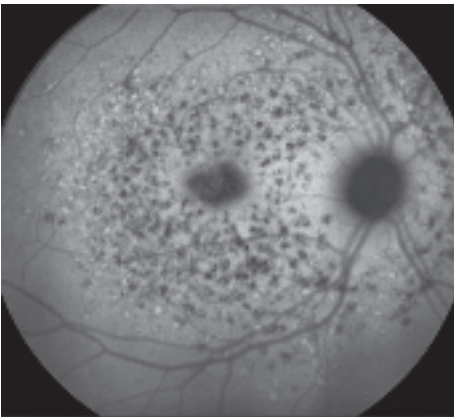
**Figure 11.30.2** Intravenous fluorescein angiography of Stargardt disease exhibiting silent choroid.

### Inheritance

Usually autosomal recessive, but occasionally autosomal dominant (dominant cases may be asymptomatic into middle age).

### Differential Diagnosis

- **Fundus albipunctatus:** Diffuse, small, white, discrete dots, most prominent in the mid-peripheral fundus and rarely present in the fovea; congenital stationary night blindness variant; no atrophic macular degeneration or pigmentary changes. Visual acuity and visual fields remain normal. Prolonged dark-adaptation time with normal ERG.



**Figure 11.30.3** Fundus autofluorescence in Stargardt disease.

- **Retinitis punctata albescens:** Similar clinical appearance to fundus albipunctatus, but visual acuity, visual field, and night blindness progressively worsen. A markedly abnormal ERG develops. Variant of RP.
- **Drusen:** Small, yellow-white spots deep to the retina, sometimes calcified, usually developing later in life. IVFA may be helpful (all drusen exhibit hyperfluorescence, whereas fundus flavimaculatus lesions show variable hyperfluorescence and some areas without flecks show hyperfluorescence).
- **Cone or cone-rod dystrophy:** May have normal fundus in early stages. May have bull's eye maculopathy, but have significant color vision deficit and a characteristic ERG. See 11.29, CONE DYSTROPHIES.
- **Batten disease and Spielmeyer-Vogt syndrome:** Autosomal recessive lysosomal storage disease characterized by progressive dementia and seizures. May have bull's eye maculopathy, variable degree of optic atrophy, attenuation of retinal vasculature, and peripheral RPE changes. Shows characteristic curvilinear or fingerprint inclusions on electron microscopy of peripheral blood or conjunctival biopsy. Variants of RP.
- **Chloroquine/hydroxychloroquine maculopathy:** History of medication use. See 11.32, CHLOROQUINE/HYDROXYCHLOROQUINE TOXICITY.
- **Nonphysiologic visual loss:** Normal ophthalmoscopic examination, IVFA, OCT, ERG, and EOG. Patients can often be tricked into seeing better by special testing. See 10.25, NONPHYSIOLOGIC VISUAL LOSS.

### Workup

Indicated when the diagnosis is uncertain or must be confirmed.

1. History: Age at onset, medications, family history?
2. Dilated fundus examination.
3. OCT may show photoreceptor disorganization, outer retinal atrophy, and RPE changes, which may appear early even with a normal fundus examination.
4. IVFA often shows blockage of choroidal fluorescence producing a "silent choroid" or "midnight fundus" as a result of increased lipofuscin in RPE cells.

5. FAF can be helpful in diagnosis and in monitoring disease progression.
6. ERG and EOG.
7. Formal visual field examination (e.g., Octopus, Humphrey).
8. Consider genetic testing: Sequencing of the ABCA4 gene (found to be abnormal in many cases of Stargardt disease and other related maculopathies).

### Treatment

Avoid vitamin A supplementation. Ultraviolet light-blocking glasses when outdoors may be beneficial. Low-vision aids, services dedicated to helping the visually handicapped, and genetic counseling are helpful.

## 11.31 Best Disease (Vitelliform Macular Dystrophy)

### Symptoms

Decreased vision, scotoma, metamorphopsia, or asymptomatic.

### Signs

(See Figure 11.31.1.)

**Critical.** Yellow, round, subretinal lesion(s) likened to an egg yolk (lipofuscin) or in some cases to a pseudohypopyon. Typically bilateral and located in the fovea, measuring approximately one to two disc areas in size. Likely present at birth, though may not be detected until examination is performed. Ten percent of lesions are multiple and extrafoveal. ERG is typically normal, while EOG is abnormal, showing severe loss of the light response.

**Other.** The lesions may degenerate, and patients may develop macular CNV (20% of patients), hemorrhage, and atrophic scarring. In the scar

stage, it may be indistinguishable from AMD. Hyperopia is common due to shortened axial length along with angle closure glaucoma; may also have esophoria or esotropia.

### Inheritance

Autosomal dominant with variable penetrance and expression. Due to mutation of the *BEST1* gene. Carriers may have normal fundi but an abnormal EOG.

### Differential Diagnosis

- Pattern dystrophy: A type of pattern dystrophy, adult-onset foveomacular dystrophy, can mimic Best disease. The egg yolk lesions are usually smaller, appearing from ages 30 to 50 years. The condition is dominantly inherited, and the EOG may or may not be abnormal. Typically due to mutation of the *PRPH2* gene, rather than *BEST1*. Visual acuity is usually normal or slightly decreased until the sixth decade of life, when central vision may be compromised by geographic atrophy. There is no effective treatment for this entity, unless CNV develops and thus anti-VEGF injections may be used to treat CNV.
- AMD: See above and 11.16, NONEXUDATIVE (DRY) AGE-RELATED MACULAR DEGENERATION.

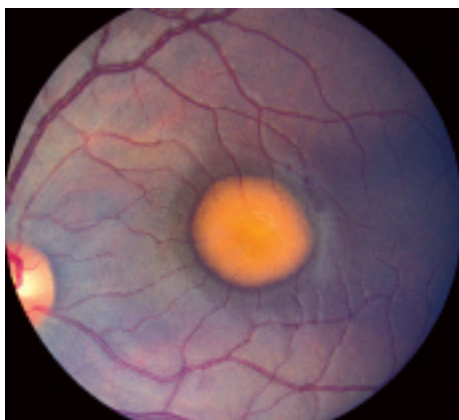


Figure 11.31.1 Best disease.

### Workup

1. Family history. It is often helpful to examine family members.
2. Complete ocular examination, including a dilated retinal examination, carefully inspecting the macula with a slit lamp and a fundus contact, or handheld (60-, 90-diopter) lens.

3. EOG is highly specific and can be used to confirm the diagnosis or to detect the carrier state of the disease.
4. Genetic testing to confirm mutation of *BEST1* gene.
5. Consider IVFA and OCT to detect the presence of or to delineate CNV.

### Treatment

There is no effective treatment for the underlying disease. Treatment for CNV is controversial because it may heal without devastating visual loss. In the era of intravitreal anti-VEGF agents, these are now typically first-line agents for CNV, but PDT and focal laser may also play

a potential role. Additionally, due to development of subretinal hemorrhage with mild trauma, polycarbonate lenses are recommended at all times and especially while playing sports. See 11.17, NEOVASCULAR OR EXUDATIVE (WET) AGE-RELATED MACULAR DEGENERATION, for detailed treatment options for CNV.

### Follow Up

Patients with CNV should be treated promptly. Otherwise, there is no urgency in seeing patients with this disease. Patients are given an Amsler grid (see Appendix 4, AMSLER GRID), instructed on its use, and told to return immediately if a change is noted.

## 11.32 Chloroquine/Hydroxychloroquine Toxicity

### Symptoms

Often asymptomatic early, then decreased vision, abnormal color vision, reduced dark adaptation.

### Signs

**Critical.** Bull's eye macula (ring of depigmentation surrounded by a ring of increased pigmentation), loss of foveal reflex.

**Other.** Increased pigmentation in the macula, arteriolar narrowing, vascular sheathing, peripheral pigmentation, decreased color vision, CME, visual field abnormalities (central, paracentral, or peripheral scotoma), abnormal ERG and EOG, and abnormal dark adaptation. Whorl-like corneal changes may also be observed.

### Major Risk Factors

- Chloroquine daily dosage: >2.3 mg/kg real weight
- Hydroxychloroquine daily dosage: >5.0 mg/kg real weight
- Duration of use: >5 years, assuming no other risk factors
- Renal disease, tamoxifen use, comorbid macular disease

### Differential Diagnosis of Bull's Eye Maculopathy

- Cone dystrophy: Family history, usually <30 years of age, severe photophobia, abnormal to nonrecordable photopic ERG. See 11.29, CONE DYSTROPHIES.

- Stargardt disease: Family history, usually <25 years of age, may have white-yellow flecks in the posterior pole and midperiphery. See 11.30, STARGARDT DISEASE (FUNDUS FLAVIMACULATUS).
- AMD: Drusen; pigment clumping, atrophy, and exudative changes in the neovascular form. See 11.16, NONEXUDATIVE (DRY) AGE-RELATED MACULAR DEGENERATION and 11.17, NEOVASCULAR OR EXUDATIVE (WET) AGE-RELATED MACULAR DEGENERATION.
- Batten disease and Spielmeier–Vogt syndrome: Pigmentary retinopathy, seizures, ataxia, and progressive dementia. See 11.30, STARGARDT DISEASE (FUNDUS FLAVIMACULATUS).

### Treatment

Discontinue the medication in conjunction with the prescribing physician if signs of toxicity develop.

### Baseline Workup

Baseline evaluation should be performed within the first year of starting the medication.

1. Best corrected visual acuity.
2. Ophthalmoscopic examination, including dilated fundus examination with particular attention to any pigmentary alterations.
3. Consider posterior pole fundus photographs.
4. Consider visual fields and OCT if maculopathy is present.



## Follow Up

After 5 years of medication use (sooner in presence of major risk factors), begin annual screening:

1. Automated visual fields: Preferably white SITA testing and 10-2 pattern for non-Asians. 24-2 or 30-2 pattern recommended for Asian patients in whom toxicity often manifests in the more peripheral macula.
2. Spectral domain OCT: Parafoveal photoreceptor layer thinning and/or disruption of outer retinal layers (“flying saucer sign”), RPE atrophy, loss of foveal contour. Consider wide angle scans including vascular arcades in Asian patients.
3. Additional tools that may be used as available or in suspect cases include multifocal ERG and FAF (see Figure 11.32.1)

**NOTE:** Once ocular toxicity develops, it usually does not regress even if the drug is withdrawn. In fact, new toxic effects may develop, and old ones may progress even after the chloroquine/hydroxychloroquine has been discontinued.

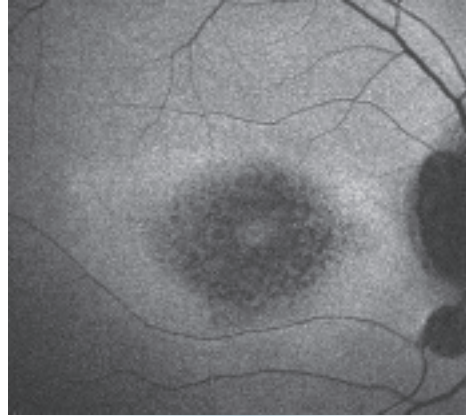


Figure 11.32.1 Fundus autofluorescence of hydroxychloroquine toxicity.

## REFERENCE

Marmor MF, Kellner U, Lai TY, et al; American Academy of Ophthalmology. Recommendations on screening for chloroquine and hydroxychloroquine retinopathy (2016 Revision). *Ophthalmology*. 2016;123(6):1386-1394.

## 11.33 Crystalline Retinopathy

### Symptoms

Decreased vision or asymptomatic.

### Signs

**Critical.** Intraretinal refractile bodies.

**Other.** If crystals are intravascular and cause capillary nonperfusion, peripheral neovascularization as well as neovascularization of the optic nerve can develop (most commonly with talc). ME, macular pucker, and VH may also occur. Skin may reveal evidence of intravenous drug abuse.

### Differential Diagnosis

- Hard exudates: Intraretinal lipid exudates as can be seen in multiple conditions (e.g., diabetic retinopathy, CRVO/BRVO, Coats disease, retinal telangiectasia, RAM). Hard exudates are not seen within retinal vessels.
- Calcific drusen: Seen in dry AMD. Drusen are subretinal, not intravascular.

### Etiology

- Canthaxanthin toxicity: Oral tanning agent causing ring-shaped deposits in the superficial retina. Generally asymptomatic and usually resolves over many years when the drug is stopped. Usually requires a total of 19 g over 2 years. Crystals appear more prominent in eyes with preexisting retinal disease and patients taking beta-carotene.
- Tamoxifen: Used in patients with hormone receptor-positive breast cancer. Toxicity usually requires 7.7 g total. Crystals appear in the inner retina usually around the macula and may cause ME. Vision may improve with discontinuation of drug, but crystals remain. Asymptomatic patients taking tamoxifen do not need to be screened. Consider medication change if evidence of toxicity in consultation with patient’s oncologist.
- Retinal arterial emboli: Seen within vessel. See 11.6, CENTRAL RETINAL ARTERY OCCLUSION and 11.7, BRANCH RETINAL ARTERY OCCLUSION.

- Talc: Red-yellow refractile particles seen intravascularly in intravenous drug users. Usually requires chronic IV drug use over several months to years before retinopathy develops.
- Methoxyflurane: An inhalational anesthetic agent. Calcium oxalate crystals deposited throughout the body can lead to irreversible renal failure. Crystals seen in both the RPE and inner retina.
- Bietti crystalline dystrophy: Crystals of unknown composition in the peripheral corneal stroma and in the retina at different layers. See 11.28, RETINITIS PIGMENTOSA AND INHERITED CHORIORETINAL DYSTROPHIES.
- Idiopathic juxtafoveal/parafoveal telangiectasis: Telangiectasis of juxtafoveal or parafoveal retinal capillaries leading to exudation and deposition of crystals on the ILM which may be Mueller foot plates or calcium or cholesterol deposits. Patients can develop ME and/or CNV. Vascular damage is very similar to that seen in diabetic retinopathy, and some patients with this condition are later found to have insulin resistance.
- Other: Nitrofurantoin toxicity, Sjögren-Larsson syndrome, West-African crystalline maculopathy, chronic RD, and others.

### Workup

1. Complete past medical and medication history: Intravenous drug use? Cardiovascular risk factors such as HTN, elevated cholesterol? Breast cancer? Use of oral tanning agents? History of anesthesia in patient with renal failure?
2. Complete ocular examination, including dilated retinal evaluation using a slit lamp

and 60- or 90-diopter lens along with indirect ophthalmoscopy. Carefully assess the location, depth, color, and morphology of crystals as well as the potential presence of ME, neovascularization of the disc and peripheral retina, or retinal infarction. Examine the cornea for crystals.

3. Consider carotid Doppler US and echocardiography in older patients and those with cardiovascular risk factors.
4. Examine patient for evidence of intravenous drug abuse.
5. Consider testing for diabetes if idiopathic juxtafoveal/parafoveal telangiectasis suspected.
6. IVFA may be helpful to demonstrate areas of nonperfusion distal to an intravascular crystal. OCT may be helpful to determine depth.

### Treatment

1. Stop tamoxifen or canthaxanthin use if responsible for toxicity.
2. Stop intravenous drug use.
3. If cholesterol, calcium, or fibrin-platelet emboli, see 10.22, TRANSIENT VISUAL LOSS/AMAUIROSIS FUGAX, 11.6, CENTRAL RETINAL ARTERY OCCLUSION, and 11.7, BRANCH RETINAL ARTERY OCCLUSION.
4. If there is peripheral nonperfusion or neovascularization, consider PRP or anti-VEGF agents. Visual loss may be permanent if there has been vascular nonperfusion in the macula secondary to blockage from intraretinal crystals.

### Follow Up

Depends on the underlying etiology.

## 11.34 Optic Pit

### Symptoms

Asymptomatic if isolated. May notice distortion of straight lines or edges, blurred vision, a blind spot, or micropsia if macular fluid develops.

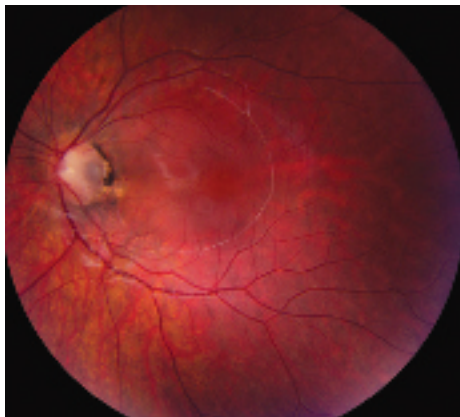### Signs

(See Figure 11.34.1.)

**Critical.** Small, round depression (usually gray, yellow, or black in appearance) in the nerve

tissue of the optic disc. Most are temporal, approximately one-third are central, but may be present anywhere on the nerve head.

**Other.** Peripapillary atrophy, white or gray membrane overlying pit, rarely RAPD, various visual field defects. May develop localized detachment of the sensory retina and/or retinoschisis extending from the disc to the macula, usually unilateral.



**Figure 11.34.1** Optic pit with associated serous macular detachment.

### Differential Diagnosis

- Acquired pit (pseudopit): Sometimes seen in patients with low-tension glaucoma or primary open-angle glaucoma. See 9.1, PRIMARY OPEN-ANGLE GLAUCOMA.
- Other causes of cyst, fluid, or hole in the macula. OCT is key. See 11.15, CENTRAL SEROUS CHORIORETINOPATHY.

### Workup

- Complete ophthalmologic examination including slit lamp examination of the optic

nerve and macula with a 60-, 90-diopter, or fundus contact lens to evaluate for macular fluid.

- Measure IOP.
- Obtain baseline automated visual field testing.
- If macular fluid is present, consider OCT to characterize precisely and IVFA to rule out CSCR or CNV.

### Treatment

1. Isolated optic pit: No treatment required.
2. Optic pit with macular fluid causing vision loss: Watchful waiting or vitrectomy and intravitreal gas are most commonly used. Laser photocoagulation to the temporal margin of the optic disc and macular buckling have also been described.

### Follow Up

1. Isolated optic pits: Yearly examination including IOP check, dilated fundus examination, and visual field testing if indicated; sooner if symptomatic. Patients should be given an Amsler grid. See Appendix 4, AMSLER GRID. Monitor for and treat amblyopia if present.
2. Optic pits with serous macular detachment or retinoschisis: Refer for retinal evaluation.

## 11.35 Solar or Photic Retinopathy

### Symptoms

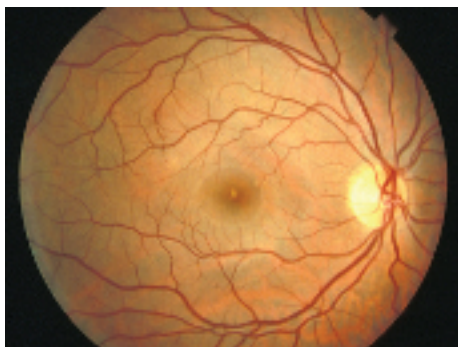Decreased visual acuity, central/paracentral scotomata, dyschromatopsia, metamorphopsia. Typically bilateral.

### Signs

(See Figure 11.35.1.)

**Critical.** Acute findings include a yellow-white spot in the fovea with or without surrounding granular gray pigmentation. Classic late finding is a red, sharply demarcated lesion in the fovea.

**Other.** Visual acuity usually ranges from 20/25 to 20/100. Amsler grid testing may reveal



**Figure 11.35.1** Solar retinopathy.




Figure 11.35.2 Optical coherence tomography of solar retinopathy.

central or paracentral scotoma. Resolution of acute findings within several weeks may leave a variable appearance to the fovea (e.g., pigmentary disturbance, lamellar hole, normal appearance, etc). Eyes with better initial visual acuities are more likely to have unremarkable fundoscopic examinations at follow up.

### Differential Diagnosis

- Macular hole or vitreomacular traction: See 11.25, VITREOMACULAR ADHESION (VMA)/VITREOMACULAR TRACTION (VMT)/MACULAR HOLE.
- Idiopathic macular telangiectasia type 2: May have OCT findings similar to those seen in chronic solar retinopathy, although on IVFA juxtafoveal capillary telangiectasis is seen with leakage. May be complicated by CNV.
- Intraretinal cysts, as for example in chronic CME, but this can be differentiated by OCT.
- Pattern dystrophy: Adult-onset foveomacular dystrophy. See 11.31, BEST DISEASE (VITELLIFORM MACULAR DYSTROPHY).

### Etiology

Unprotected solar eclipse viewing, sungazing (e.g., related to religious rituals, psychiatric illnesses, hallucinogenic drugs), sunbathing, vocational

exposure (e.g., aviation, military service, astronomy, arc welding)

### Workup

- History: Eclipse viewing or sungazing? Work exposure? Photosensitizing medications?
- Complete ocular examination, including a dilated fundus examination and careful inspection of the macula with a slit lamp using a 60-, 90-diopter, or fundus contact lens.
- Amsler grid testing may identify central or paracentral scotomata.
- IVFA typically shows a window defect late in the disease course.
- OCT findings in the acute setting include hyporeflectivity at the level of the RPE and occasional hyperreflectivity of the injured neurosensory retina. In the chronic stage, a central hyporeflective defect at the level of the photoreceptor inner segment–outer segment junction is seen (see Figure 11.35.2).

### Treatment

1. Observation. Eyes with better visual acuities on initial examination tend to recover more vision. Long-term significant reduction in visual acuity is rare. However, central or paracentral scotomata may persist despite improvement in visual acuity.

## 11.36 Choroidal Nevus and Malignant Melanoma of the Choroid

### CHOROIDAL NEVUS

#### Symptoms

Usually asymptomatic. Rare symptoms include flashes of light (if SRF present) or decreased visual acuity (if directly subfoveal).

#### Signs

(See Figure 11.36.1.)

**Critical.** Flat or minimally elevated pigmented or nonpigmented choroidal lesion.

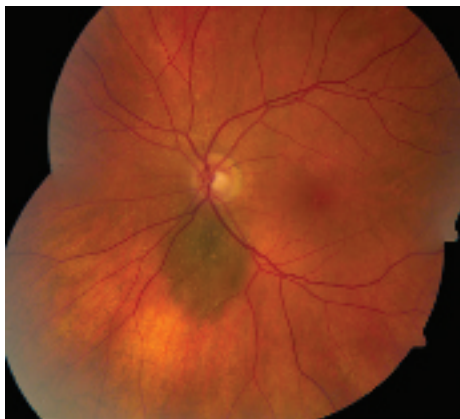


Figure 11.36.1 Choroidal nevus.

**Other.** Usually <2 mm thick with gradual elevation from the choroid. Overlying drusen become more prominent with age and can appear as hard cuticular drusen or soft drusen. RPE atrophy, hyperplasia, and detachment can occur. Rarely, overlying orange pigment (lipofuscin) or SRF is detected. Minimal growth of <1 mm over many years can be found. If >1 mm growth is observed over shorter period (1 year), transformation into melanoma should be considered.

### Risk Factors for Malignant Transformation

These are remembered by the mnemonic “to find small ocular melanoma doing imaging” whereby the first letter of each word (TFSOM-DIM) represents a risk factor found using multimodal imaging.

- T: Thickness >2 mm (US).
- F: Fluid subretinal (OCT).
- S: Symptoms (vision loss, <20/50 on Snellen visual acuity).
- O: Orange pigment hyperautofluorescence (autofluorescence).
- M: Melanoma hollow (US).
- DIM: Diameter >5 mm (photography).

**NOTE:** If four or more factors are present, the lesion has a >50% chance to show growth and is likely to be a small choroidal melanoma.

### Differential Diagnosis

See below for differential diagnosis of pigmented/nonpigmented choroidal lesions.

### Workup

1. Complete ophthalmologic examination including dilated fundus examination with evaluation of the lesion using a 20-diopter lens.
2. Detailed clinical drawing of the lesion with careful attention to location and size.
3. Baseline color photos of the lesion to assist in diameter assessment and in documenting growth.
4. OCT to document the overlying retinal features, SRF, and the lesion itself using enhanced-depth imaging.
5. Autofluorescence to document the presence of lipofuscin or RPE disturbance.
6. US for tumor thickness measurement and internal acoustic qualities.

### Treatment

Observation. First examination should be in 3 to 4 months to confirm stability and then one to two times yearly to document lack of change.

### Follow Up

Low-risk lesions can be followed with annual dilated fundus examination. High-risk lesions should be followed every 3 to 6 months.

## MALIGNANT MELANOMA OF THE CHOROID

### Symptoms

Decreased vision, visual field defect, floaters, light flashes, rarely pain; often asymptomatic.

### Signs

(See Figure 11.36.2.)

**Critical.** Gray-green or brown (melanotic) or yellow (amelanotic) choroidal mass that exhibits one or more of the following:

- Presence of SRF.
- Thickness  $\geq 2$  mm, especially with an abrupt elevation from the choroid.

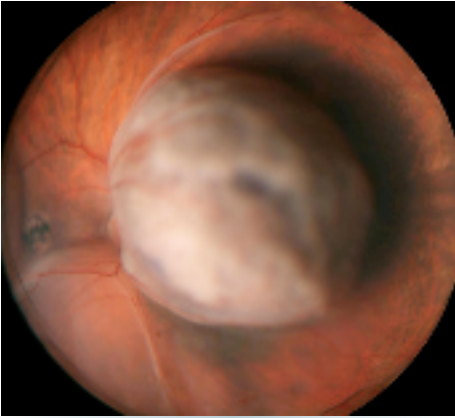

Figure 11.36.2 Choroidal melanoma.

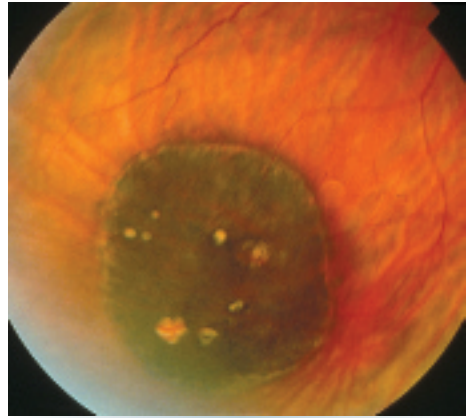


Figure 11.36.3 Congenital hypertrophy of the retinal pigment epithelium.

- Ill-defined, large areas of geographic orange pigment over the lesion.
- A dome, mushroom, or plateau shape with congested blood vessels in the apex of the tumor.
- Break in Bruch membrane with subretinal hemorrhage.
- Growth.



**NOTE:** A diffuse choroidal melanoma can appear as a minimally thickened dark choroidal lesion without a prominently elevated mass and can simulate a nevus.

**Other.** Overlying cystoid retinal degeneration, VH or vitreous pigmented cells, drusen on the tumor surface, CNV, proptosis (from orbital invasion). Choroidal melanoma rarely occurs in darker pigmented individuals and more commonly occurs in light-skinned, blue- or green-eyed individuals.

### Differential Diagnosis of Pigmented Lesions

- Choroidal nevus: See above.
- Congenital hypertrophy of the RPE: Flat black lesions that have crisp margins and often occur in the peripheral fundus. The margins are often well delineated with a surrounding depigmented and pigmented halo. Depigmented lacunae within the lesion appear as the lesion ages. Asymptomatic (see Figure 11.36.3).
- Reactive hyperplasia of the RPE: Related to previous trauma or inflammation. Lesions are black, flat, have irregular margins, and may have associated white gliosis. Often multifocal.
- Subretinal blood: From any cause can simulate a melanoma, including AMD, IPCV, PEHCR, others. IVFA and ICGA may aid in differentiation. See specific sections.
- Melanocytoma of the optic nerve: A black optic nerve lesion with fibrillated margins. It can grow slowly in approximately 15% cases. IVFA may allow differentiation.
- Choroidal detachment: Follows ocular surgery, trauma, or hypotony of another etiology. Dark peripheral multilobular fundus mass. The ora serrata is often visible without scleral depression. Localized suprachoroidal hemorrhage can be very difficult to differentiate from melanoma based on appearance alone. Transillumination may help distinguish a serous choroidal detachment (but not hemorrhagic) from melanoma. In these situations, IVFA is the study of choice, usually allowing differentiation between the two entities. See 11.27, CHOROIDAL EFFUSION/DETACHMENT.

### Differential Diagnosis of Nonpigmented Lesions

- Choroidal hemangioma: Red-orange, may be elevated, not mushroom shaped.
- Metastatic carcinoma: Cream or light brown, flat or slightly elevated, extensive SRF, may be multifocal or bilateral. Patient may have

a history of cancer (especially breast or lung cancer).

- Choroidal osteoma: Yellow-orange, usually close to the optic disc, pseudopod-like projections of the margin; often bilateral; typically occurs in young women in their teens or twenties. US may show a minimally elevated, calcified plaque-like lesion.
- Posterior scleritis: Patients may have choroidal folds, pain, proptosis, uveitis, or anterior scleritis associated with an amelanotic mass. Look for the T-sign on US. See 5.7, SCLERITIS.
- Lymphoma: Yellow-orange infiltration; can be unilateral or bilateral; often there is associated orbital or conjunctival lymphoma.
- Sclerochoroidal calcification: Asymptomatic, yellow-white, sub-RPE, and subchoroidal plaques. Typically bilateral and commonly postequatorial and superotemporal. May be elevated. May be the result of calcification of the insertion of the oblique muscles. B-scan US shows an elevated, calcified lesion. Typically idiopathic and seen in elderly patients. Can be associated with abnormalities of calcium-phosphorus metabolism and cases of renal tubular hypokalemic metabolic alkalosis (e.g., Gitelman and Bartter syndromes). Renal function, parathyroid hormone, and serum electrolytes including calcium and magnesium should be checked.

### Workup

1. History: Ocular surgery or trauma, cancer, anorexia, weight loss, or systemic illness?
2. Dilated fundus examination using indirect ophthalmoscopy.
3. IVFA: Can rule out lesions that simulate melanoma, but may not differentiate melanoma from large nevus, metastases, or hemangioma.
4. A-scan and B-scan US: Documents thickness and confirms clinical impression. With choroidal melanoma, US usually shows low-to-moderate reflectivity with choroidal excavation. Thickness is often >2 mm. May show a mushroom appearance.
5. OCT: Often documents fresh SRF.
6. Autofluorescence: Often shows prominent overlying lipofuscin (orange pigment).
7. ICGA: Can show double circulation with prominent blood vessels within the melanoma.
8. Consider fine-needle aspiration biopsy for genetic analysis of the tumor for prognostication and in selected cases for cytologic confirmation.
9. Consider CT scan or MRI of the orbit and brain (useful in patients with opaque media):
  - If melanoma is confirmed, systemic follow up is done according to the risk level for metastatic disease. Blood work: Lactate dehydrogenase, gamma-glutamyl transferase, aspartate and alanine aminotransferases, and alkaline phosphatase twice yearly. If liver enzymes are elevated, consider an MRI or liver scan to rule out liver metastases.
  - Annual chest x-ray.
  - Annual MRI of the liver.
  - Annual complete physical examination by a medical internist or oncologist.
10. Referral to an internist or oncologist for breast examination, full skin examination, chest CT, and possibly a carcinoembryonic antigen assay if choroidal metastases are suspected.

### Treatment

Depending on the results of the metastatic workup, the tumor characteristics, the status of the contralateral eye, and the age and general health of the patient, melanoma of the choroid may be managed by observation, photocoagulation, transpupillary thermotherapy, radiation therapy, local resection, enucleation, or exenteration. Most cases are managed with plaque radiotherapy. Anti-VEGF injections every 4 months for the first 2 years have been shown to minimize ultimate vision loss from radiation retinopathy. In some cases, sector photocoagulation is added.

### REFERENCES

- Shields CL, Dalvin LA, Ancona-Lezama D, et al. Choroidal nevus imaging features in 3,806 cases and risk factors for transformation into melanoma in 2,355 cases: the 2020 Taylor R. Smith and Victor T. Curtin lecture. *Retina*. 2019;39(10):1840-1851.
- Shields CL, Dalvin LA, Chang M, et al. Visual outcome at 4 years following iodine-125 plaque radiotherapy and prophylactic intravitreal bevacizumab (every 4 months for 2 years) for uveal melanoma in 1131 patients. *JAMA Ophthalmol*. 2019;138(2):136-146. doi:10.1001/jamaophthalmol.2019.5132